

P16^{INK4A} EXPRESSION AS A POTENTIAL PROGNOSTIC MARKER IN CERVICAL PRECANCEROUS AND CANCEROUS LESIONS IN MOROCCO

Yassine Zouheir

Laboratory of histo-cytopathology of Institut Pasteur of Morocco, Casablanca, Morocco; Laboratory of Neurosciences, Integrated diseases and natural Substances, Faculty of sciences and Technics, Mohammedia, Hassan II University, Morocco

Taoufiq Fechtali

Laboratory of Neurosciences, Integrated diseases and natural Substances, Faculty of sciences and Technics, Mohammedia, Hassan II University, Morocco

Nadia Elgnaoui

Laboratory of histo-cytopathology of Institut Pasteur of Morocco, Casablanca, Morocco.

Abstract

Introduction :The overexpression of p16^{INK4a} is considered to be strong and consistent in HPV-induced cancers. The objective of this study was to investigate the presence of HPV DNA in cervical biopsies, and to study the overexpression of p16INK4a as a marker of precancerous and cancerous lesions of the cervix.

Material and methods :A total of 75 cervical biopsies were included in this study involving cervicitis (n = 11), mild dysplasia (n = 17), severe dysplasia (n = 30) and invasive carcinomas (n = 17). The presence of HPV was assessed using an examination in situ hybridization (CSA). p16^{INK4a} protein expression was investigated by immunohistochemistry.

Results: p16^{INK4a} expression was very low in benign cervical lesions, while 18.8% of these lesions showed positivity for HPV DNA detection. Forty seven percent of mild dysplastic lesions presented overexpression of p16^{INK4a} protein, and 76.4% were HPV positive. Strong signal of p16^{INK4a} was observed in 100% of severe dysplastic lesions, and in 94.2% of invasive carcinoma. HPV DNA was detected in 83.3% of severe dysplastic lesions, and in 82.3% of invasive carcinoma.

Conclusion: This pattern of overexpression demonstrates the potential use of p16^{INK4a} as a diagnostic marker to recognize evolution of precancerous disease in the cervix.

Keywords: P16^{INK4a} protein- Cervical cancer- Immunohistochemistry-HPV- In situ hybridization (CSA).

Introduction

Human papillomaviruses (HPV) are known to be a major causative agent in cervical neoplasia and invasive cervical carcinoma. HPVs have circular, double-stranded DNA genomes that are approximately 8 kb in size and encode eight genes, of which E6 and E7 have transforming properties. The ability of high-risk HPV E7 protein to associate with the tumor suppressors pRB has been suggested as a mechanism by which this viral protein induce tumor (Crook, Tidy et al. 1991). p16^{INK4a} is a cyclin-dependent kinase inhibitor that regulates the activity of cyclin-dependent kinases 4 and 6. When the HPV E7 oncoprotein inactivates retinoblastoma, p16 expression increases dramatically (Phelps, Yee et al. 1988; Dyson, Howley et al. 1989; Koh, Enders et al. 1995; Jedpiyawongse, Homcha-em et al. 2008). p16^{INK4a} overexpression in some types of tumors, such as cervical cancer, is used as a diagnostic tool and has been directly associated with infection by high risk (HR) HPV genotypes (Masumoto, Fujii et al. 2003; Mulvany, Allen et al. 2008). The aim of this study was to investigate the presence of HPV DNA in cervical biopsies, and to study the overexpression of p16^{INK4a} as a biomarker of precancerous and cancerous lesions on biopsy specimens of the uterine cervix due to abnormal cytological finding.

Material and methods

Seventy five cervical biopsies were included in the study; they were identified in the laboratory of histo-cytopathology of Institut Pasteur du Maroc. The samples were fixed in 10% formalin and embedded in paraffin. Sections of 3-4 microns paraffin were placed on silanized slides. Initially, the samples were subjected to histopathological study by hematoxylin-eosin conventional technique (H&E). Secondly, immunohistochemistry was performed to assess the expressions of p16^{INK4a} protein, we used the protocol of CINtec Histology Kit (Biogen/Roche, Germany), according to the manufacturer's protocol. The samples were incubated overnight at 37 ° C, then at 60 ° C for 30 minutes, after which they were dewaxed in three successive baths of xylene (15 minutes for each bath). This was followed by rehydration through successive passage of the sections through four alcohol

baths with decreasing concentrations (100% alcohol, 90% alcohol, 80% alcohol, 70% alcohol), for approximately 10 minutes per each bath.

After incubation with primary mouse monoclonal antibody against human p16^{INK4a} protein (clone designation E6H4), visualization is based on a dextran technology. The reagent consists of both molecules secondary immunoglobulin and goat anti-mouse horseradish peroxidase molecules linked to a common dextran polymer support, thereby removing the need for sequentially applying binding antibody and peroxidase-conjugated antibody. The enzymatic conversion by the chromogen (AEC) results in the formation of a visible precipitate at the antigen site. The slides were stained with cons-Mayer hematoxylin and mounted in aqueous medium. The results were evaluated using an optical microscope. The reaction is considered positive when the cell shows a brownish color at the nuclear level and / or cytoplasmic. The slides were then counterstained with Mayer's hematoxylin and mounted in aqueous medium. The results were evaluated using an optical microscope. The reaction was considered as positive when the cell showed a brownish color at the nuclear level and / or cytoplasmic. The immunoreactivity results of anti-p16^{INK4a} antibodies were determined by applying a semi-quantitative scale described by *Klaes et al.* (Klaes, Friedrich et al. 2001) :

- Negative: less than 1% of cells are positive.
- Sporadic: isolated positive cells, but less than 5%.
- Focal: small cell clusters, but less than 25% of the positive cells.
- Diffuse: more than 25% of stained cells.

HPV detection

To detect HPV DNA, all cervical biopsies were subjected to in situ hybridization with the amplification signal (HIS CSA) using a biotinylated probe with broad spectrum. Following dewaxing and hydration, proteolytic digestion was performed by proteinase K. The denaturation of probe and target DNA was carried out on a hotplate at 95 ° C and transferred to 37 ° C for hybridization. The reaction product was revealed using the system "GenPoint DAKO," which creates an additional level of amplification of the signal, its principle is based on the use of highly sensitive tyramide for the detection of biotinylated probes in cell and tissue preparations. Revelation of the hybridization signal was produced by a chromogenic indicator, diaminobenzidine (DAB), which oxidized by peroxidase gives a brownish precipitate at the hybridization site.

The slides were counterstained with Mayer's hematoxylin, dehydrated and mounted by the Permanent Mounting Medium (DAKO), then examined by light microscope.

Results

Histopathological examination

The histopathological diagnosis of the 75 studied biopsies revealed: 11 cervicitis, 17 mild dysplasia, 30 severe dysplasia and 17 invasive cancers (Table 1).

Table 1: Lesions diagnosed by histopathology

Lesions	Number	%
Cervicitis	11	17
Mild dysplasia	17	26
Severe dysplasia	30	31
Invasive carcinoma	17	26
Total	75	100

Immunohistochemical examination

As shown in Table 2, all cases of cervicitis were negative with immunostaining of p16^{INK4a} protein, 47% of mild dysplasia were positive while severe dysplasias and invasive carcinomas showed overexpression of p16^{INK4a} in 100% and 94.2% of cases respectively.

Table 2: Results of Immunolabeling protein p16INK4a

Lesions	Negative p16 ^{INK4a} protein	Positive p16 ^{INK4a} protein
cervicitis (n=11)	11 (100%)	0
mild dysplasia (n=17)	9 (53%)	8 (47%)
severe dysplasia (n=30)	0	30 (100%)
invasive carcinoma (n=17)	1 (5,8%)	16 (94,2)

Immunoreactivity results of the anti-p16^{INK4a} antibodies were determined by the implementation of a semi quantitative scale and were showed in Figures 1, 2, 3 and 4. Thus, in our series, immunostaining of the p16^{INK4a} protein was sporadic, focal and diffuse in 10%, 70% and 20% of mild dysplasia respectively. Focal and diffuse immunostaining were observed in 44% and 66% of severe dysplasia, respectively. While in invasive cancers, immunostaining was focal in 17% of cases and diffuse in 83% of cases (Table 3).

Table 3: Immunolabelling type of overexpression of p16^{INK4a} protein

Lesions	Sporadic (%)	Focal (%)	Diffuse (%)
Mild dysplasia (n=8)	10	70	20
Severe dysplasia (n=30)	0	44	66
Invasive carcinoma (n=16)	0	17	83

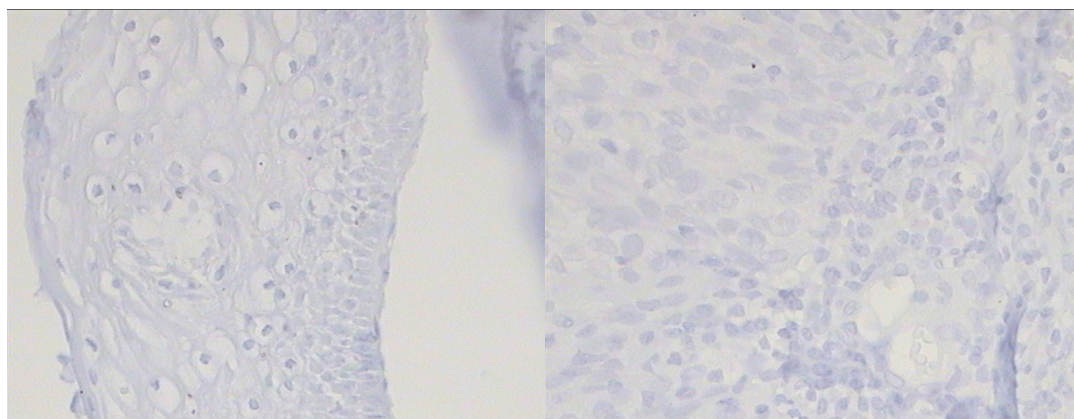
Overexpression of p16^{INK4a} protein and detection of HPV

To determine the relation between the overexpression of p16^{INK4a} protein and the presence of HPV in cervical lesions, we performed a detection of HPV by HIS (CSA) using a probe with broad spectrum for all biopsies; the results were reported in Table 4. In the cervicitis group, none of

the cases showed p16^{INK4a} protein overexpression, whereas 18.2% (2/17) of these lesions showed positivity for HPV detection. Forty seven percent (8/17) of mild dysplasia were positive for the overexpression of p16^{INK4a} protein and 76.4% (13/17) were HPV positive. In severe dysplasia and invasive cancer, a positive reaction for the p16^{INK4a} protein immunostaining was observed in 100% (30/30) and 94.2% (16/17) of cases, respectively, while HPV was detected in 83.3% (25/30) of severe dysplasia and 82.3% (14/17) of cases of cancer.

Table 4: Results of the overexpression of p16^{INK4a} protein and HPV detection

Lesions	Proteine p16 ^{INK4a}		HPV (Detection)	
	Positive	Negative	Positive	Negative
cervicitis (n=11)	0	11 (11%)	2 (18,2%)	9 (81,8%)
mild dysplasia (n =17)	8 (47%)	9 (53%)	13 (76,4%)	4 (23,6%)
severe dysplasia (n= 30)	30 (100%)	0	25 (83,3%)	5 (16,7%)
invasive carcinoma (n= 17)	16 (94,2%)	1 (5,8%)	14 (82,3%)	3 (17,7%)



A

B

Figure 1: Overexpression of p16^{INK4a} protein in cervical Biopsy (G x 40), negative control.

A: Mild dysplasia
B: Invasive cancer

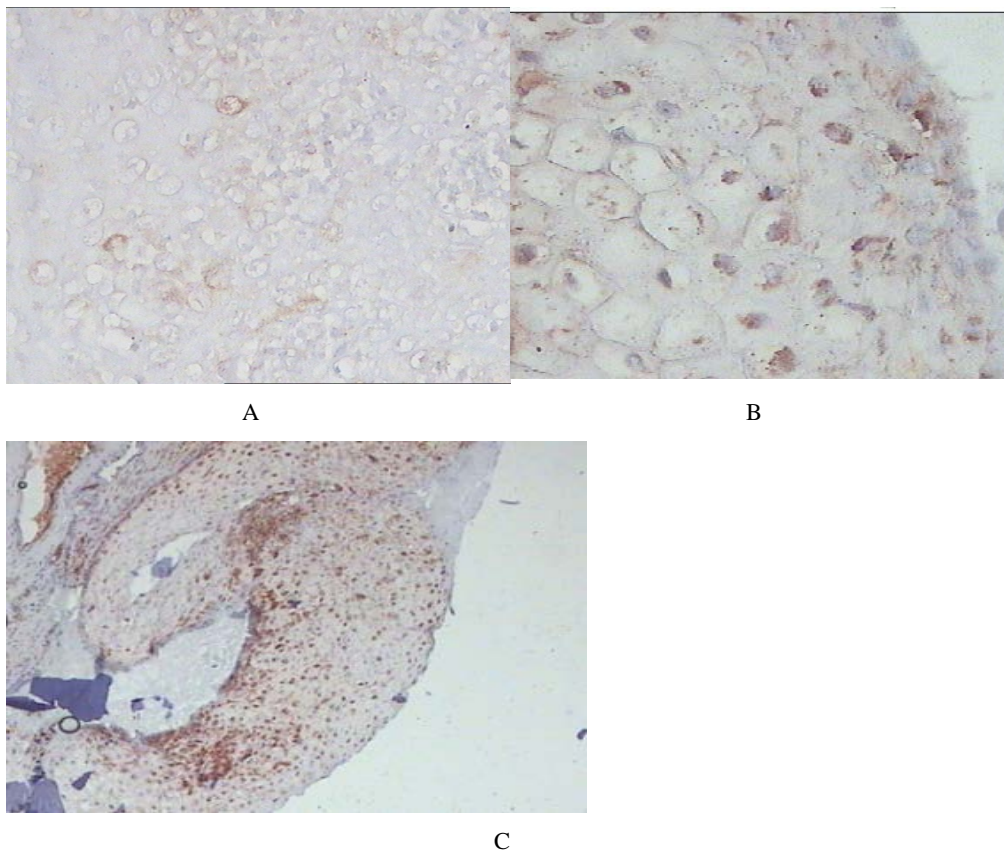


Figure 2: Positive overexpression of the protein p16^{INK4a}: Mild dysplasia.
A: Sporadic Immunolabeling (G x 20)
B: Focal Immunolabeling (G x 40)
C: Immunolabeling diffuse (G x 20)

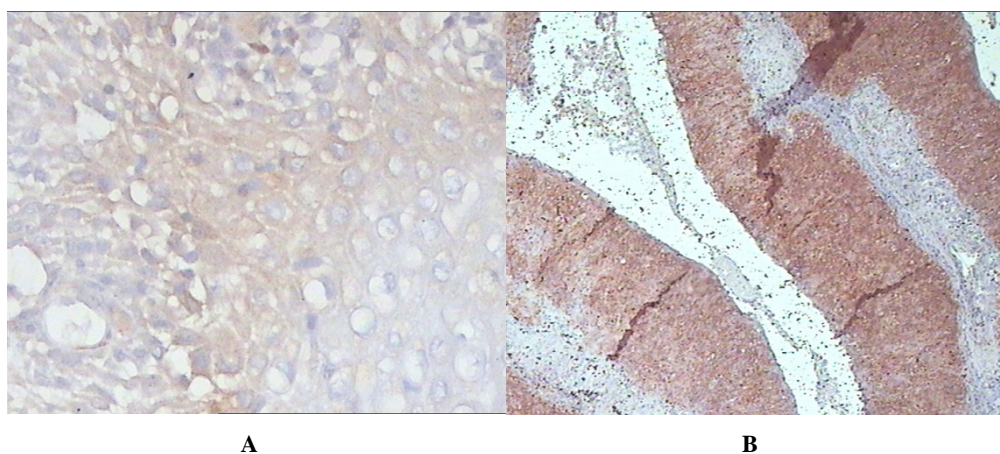


Figure3: Positive overexpression of the protein p16^{INK4a} : severe dysplasia.
A: Focal Immunolabeling (G x 40)
B: Immunostaining diffuse (G x 20)

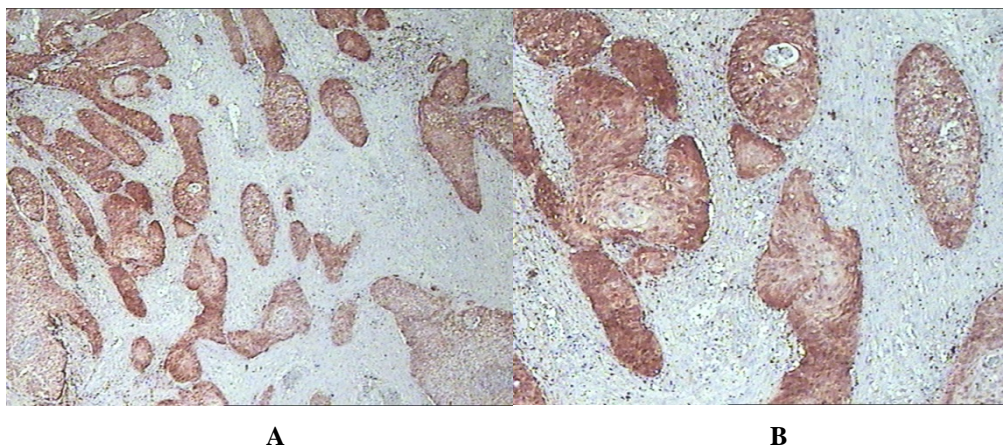


Figure 4: : Diffuse immunostaining of the protein p16^{INK4a}: Invasive cancer (A: G x 20), (B: G x 40)

Discussion

The causal role of persistent infection with HPV oncogene in the development of cervical cancer has been confirmed (Walboomers, Jacobs et al. 1999; Bosch, Lorincz et al. 2002; Munoz, Bosch et al. 2003). Strong overexpression of p16^{INK4a} has been reported in various uterine tumors, particularly in cervical cancer associated with infection by an HPV oncogene (Sano, Oyama et al. 1998; Agoff, Lin et al. 2003; Negri, Vittadello et al. 2004). Due to the association between p16^{INK4a} protein overexpression and the presence of intraepithelial neoplasia, many studies have assessed the benefit of p16^{INK4a} protein detection by immunohistochemistry in the diagnosis of histological and cytological specimens of the cervix (Klaes, Benner et al. 2002; Bergeron, Wentzensen et al. 2006). The aim of this study was to investigate the presence of HPV DNA in cervical biopsies, and to study the overexpression of p16^{INK4a} as a biomarker of precancerous and cancerous lesions on biopsy specimens of the uterine cervix.

In our series, all cases of cervicitis were negative with immunostaining of p16^{INK4a} protein, 47% of mild dysplasia were positive, while severe dysplasia and invasive cancers showed overexpression of p16^{INK4a} protein in 100% and 94.2% of cases respectively. The results of the immunoreactivity of anti-p16^{INK4a} antibody were determined by the application of a semi quantitative scale described by *Klaes et al.* (Klaes, Friedrich et al. 2001). These results were similar to those reported in many studies, where nearly 100% of high grade lesions and invasive cancers showed a strong overexpression of p16^{INK4a} protein, while non-dysplastic lesions remained negative (Calil, Edelweiss et al. 2014). In a Spanish study,

91.7% of invasive cervical cancers showed a positive overexpression of p16^{INK4a} protein with a diffuse immunostaining (Perez, Castillo et al. 2014). Agoff *et al.* reported in his study that 91% of cervical cancers with overexpression of p16^{INK4a} protein were associated with infection by oncogenic HPV, which allowed him to deduce that p16^{INK4a} protein might be a potential marker of cervical neoplasia screening (Agoff, Lin et al. 2003).

Our findings showed a weak immunostaining in mild dysplasia, which were similar to results obtained by Sano *et al.* and Lesnikova *et al.*; they marked an overexpression of p16^{INK4a} protein in high-grade dysplastic lesions and also in invasive cervical cancers, associated with infection by an oncogene HPV. However, in genital warts and mild dysplasia immunoreaction was low (Sano, Oyama et al. 1998; Lesnikova, Lidang et al. 2009). Another study, conducted in china, reported that 43.1% of cervical cancers were positive for overexpression of p16^{INK4a} protein. Immunostaining was found reduced in mild dysplasia (Jin, Zhang et al. 2000). Contradictory, a large meta-analysis of 15 publications comprised 1633 cases, showed that p16^{INK4a} overexpression was not significantly associated with tumor TNM staging (Lin, Albers et al. 2014).

About nineteen percent of cervicitis cases showed positivity of HPV. For mild dysplasia, 76.4% were HPV positive. For severe dysplasia and invasive cancers, the HPV was detected in 83.3% and 82.3% of cases respectively. During an infection by an oncogene HPV, p16^{INK4a} protein is induced in the basal cells of the cervical squamous epithelium through the expression of viral oncogenes E6 and E7. This overexpression is attributed to interference between the expression of the viral oncogene E7 that associates with the gene product pRb. The pRb gene is usually linked to E2F which blocks the activation of the cell cycle by a phosphorylation mechanism. The release of E2F-induced link between E7 and pRb gene results in a significant negative feedback repression of gene p16^{INK4a} transcription (Narisawa-Saito and Kiyono 2009; Yugawa and Kiyono 2009).

Conclusion

In total, the overexpression of p16^{INK4a} protein indicates the inactivation of cell cycle control mediated by oncogenic HPV oncoproteins. At the end of this study, we can conclude that p16^{INK4a} protein could be a promising marker for the diagnosis of precancerous and cancerous lesions of the cervix; it can highlight a persistent viral infection with an oncogenic HPV.

References

- Karcheva M, Popovska S, Navhev R. Immunohistochemical investigations of p16INK4A expression in carcinomas and high grade cervical lesions. *Am J Surg Pathol* 2007; 25: 884-891."
- Agoff, S. N., P. Lin, et al. (2003). "p16(INK4a) expression correlates with degree of cervical neoplasia: a comparison with Ki-67 expression and detection of high-risk HPV types." *Mod Pathol* **16**(7): 665-673.
- Bergeron, C., N. Wentzensen, et al. (2006). "[The p16INK4a protein: a cytological marker for detecting high grade intraepithelial neoplasia of the uterine cervix]." *Ann Pathol* **26**(5): 397-402.
- Bosch, F. X., A. Lorincz, et al. (2002). "The causal relation between human papillomavirus and cervical cancer." *J Clin Pathol* **55**(4): 244-265.
- Calil, L. N., M. I. Edelweiss, et al. (2014). "p16 INK4a and Ki67 expression in normal, dysplastic and neoplastic uterine cervical epithelium and human papillomavirus (HPV) infection." *Pathol Res Pract* **210**(8): 482-487.
- Crook, T., J. A. Tidy, et al. (1991). "Degradation of p53 can be targeted by HPV E6 sequences distinct from those required for p53 binding and trans-activation." *Cell* **67**(3): 547-556.
- Dyson, N., P. M. Howley, et al. (1989). "The human papilloma virus-16 E7 oncoprotein is able to bind to the retinoblastoma gene product." *Science* **243**(4893): 934-937.
- Jedpiyawongse, A., P. Homcha-em, et al. (2008). "Immunohistochemical overexpression of p16 protein associated with cervical cancer in Thailand." *Asian Pac J Cancer Prev* **9**(4): 625-630.
- Jin, S. L., Z. S. Zhang, et al. (2000). "[The expression of p16 and Rb protein in the tissue of cervical squamous carcinoma]." *Hunan Yi Ke Da Xue Xue Bao* **25**(4): 393-396.
- Klaes, R., A. Benner, et al. (2002). "p16INK4a immunohistochemistry improves interobserver agreement in the diagnosis of cervical intraepithelial neoplasia." *Am J Surg Pathol* **26**(11): 1389-1399.
- Klaes, R., T. Friedrich, et al. (2001). "Overexpression of p16(INK4A) as a specific marker for dysplastic and neoplastic epithelial cells of the cervix uteri." *Int J Cancer* **92**(2): 276-284.
- Koh, J., G. H. Enders, et al. (1995). "Tumour-derived p16 alleles encoding proteins defective in cell-cycle inhibition." *Nature* **375**(6531): 506-510.
- Lesnikova, I., M. Lidang, et al. (2009). "p16 as a diagnostic marker of cervical neoplasia: a tissue microarray study of 796 archival specimens." *Diagn Pathol* **4**(22): 1746-1596.
- Lin, J., A. E. Albers, et al. (2014). "Prognostic significance of overexpressed p16INK4a in patients with cervical cancer: a meta-analysis." *PLoS One* **9**(9).

- Masumoto, N., T. Fujii, et al. (2003). "P16 overexpression and human papillomavirus infection in small cell carcinoma of the uterine cervix." Hum Pathol **34**(8): 778-783.
- Mulvany, N. J., D. G. Allen, et al. (2008). "Diagnostic utility of p16INK4a: a reappraisal of its use in cervical biopsies." Pathology **40**(4): 335-344.
- Munoz, N., F. X. Bosch, et al. (2003). "Epidemiologic classification of human papillomavirus types associated with cervical cancer." N Engl J Med **348**(6): 518-527.
- Narisawa-Saito, M. and T. Kiyono (2009). "[Mechanisms of high-risk human papillomavirus-induced cervical carcinogenesis]." Nihon Rinsho **67**(1): 53-61.
- Negri, G., F. Vittadello, et al. (2004). "p16INK4a expression and progression risk of low-grade intraepithelial neoplasia of the cervix uteri." Virchows Arch **445**(6): 616-620.
- Perez, C., M. Castillo, et al. (2014). "Evaluation of p16(INK4a) overexpression in a large series of cervical carcinomas: concordance with SPF10-LiPA25 PCR." Int J Gynecol Pathol **33**(1): 74-82.
- Phelps, W. C., C. L. Yee, et al. (1988). "The human papillomavirus type 16 E7 gene encodes transactivation and transformation functions similar to those of adenovirus E1A." Cell **53**(4): 539-547.
- Sano, T., T. Oyama, et al. (1998). "Expression status of p16 protein is associated with human papillomavirus oncogenic potential in cervical and genital lesions." Am J Pathol **153**(6): 1741-1748.
- Walboomers, J. M., M. V. Jacobs, et al. (1999). "Human papillomavirus is a necessary cause of invasive cervical cancer worldwide." J Pathol **189**(1): 12-19.
- Yugawa, T. and T. Kiyono (2009). "Molecular mechanisms of cervical carcinogenesis by high-risk human papillomaviruses: novel functions of E6 and E7 oncoproteins." Rev Med Virol **19**(2): 97-113.