



## Immediate Loading of Dental Implants with Fixed Prosthodontic Constructions- Advantages and Methods

*Tamar Dolidze, Professor*

*Marika Kublashvili, Professor*

Grigol Robakidze University, School of Medicine

Doi: [10.19044/esipreprint.9.2022.p765](https://doi.org/10.19044/esipreprint.9.2022.p765)

Approved: 03 October 2022

Posted: 05 October 2022

Copyright 2022 Author(s)

Under Creative Commons BY-NC-ND

4.0 OPEN ACCESS

*Cite As:*

Dolidze T. & Kublashvili M. (2022). *Immediate Loading of Dental Implants with Fixed Prosthodontic Constructions-Advantages and Methods*. ESI Preprints.

<https://doi.org/10.19044/esipreprint.9.2022.p765>

### Abstract

“Immediate loading of implants” implies loading of implants after extraction of a tooth. The goal of our study was to observe the loss of keratinized gums and bone tissue in the region surrounding the alveolar ridge after tooth extraction, and to compare it to the immediate loading of dental implants with the same indicator.

Recently, immediate implant placement after the extraction of a tooth with early loading has become more common. The advantages of this procedure include fewer surgical interventions, reduction in overall treatment time, reduced soft and hard tissue loss, and psychological satisfaction for the patient. This study shows the advantages and methods for immediate implant placement with immediate provisional restorations.

**Keywords:** Keratinized gum, Immediate loading of implants, alveolar ridge, repeated augmentation, xenograft

## Introduction

The cause of bone and/or soft tissue loss after an extraction can be:

### 1. Anatomical Characteristics

Anatomically, in the alveolar ridge region, we have a bilateral vestibule-oral cortical plate, supporting alveolar bone and plastic alveolar bone (inner cortical plate “Lamina Dura”). The latter is the result of the concavity of the outer cortical plate, which enters the alveolar part and surrounds the root. Lamina dura is very well visualized during radiological research as a thin cortical radiopaque contour located between the periodontal fissure and the cancellous bone. The lamina dura receives nutrition from the periodontium and is connected to the root cement by Sharpay fibers. After tooth extraction, the bone is resorbed and only the surrounding, or supporting, bone remains.

The degree and intensity of alveolar ridge remodeling after extraction depends on many factors. The most important of them are the anatomical characteristics, that must be considered during tooth extraction, especially in the frontal area:

- 1) Positioning of the tooth root in the alveolar cavity. When the thickness of the vestibular wall is less than 1 mm in the frontal area, more than 2/3 of the root length is resorbed. The greater the volume of supporting bone on the vestibular side, less is the bone loss. “MA. Atieh, NHM. Alsabeeha, AGT. Payne, S. Ali, CM Jr Faggion, M Esposito. (2021)”
- 2) Alveolar ridge width. In the case of a thin alveolar ridge, even a slight loss of bone volume may render the implantation impossible. The alveolar ridge is mainly resorbed in a horizontal direction from the vestibular side. The vertical dimensions change slightly during the first 6 months and the ridge takes the shape of a triangle.

To prevent the resorption of the alveolar ridge, the method of preservation of the socket after a tooth extraction during which a bone graft is inserted into the socket, is quite relevant in recent years, to preserve the bone parameters. Loading of dental implants is performed 6 months after augmentation.

Studies confirmed that the difference in bone loss between the control and test groups during preservation was 1.83 mm. “G. Avilo-Ortiz, S. Elangovan, K.W.O. Kramer, D. Blanchette, D.V. Dawson (2014.)” Bone resorption is inevitable after tooth extraction, but the loss is relatively less in the case of conservation. This result is especially important when we have a narrow alveolar ridge.

The studies also found that after preservation of the tooth socket, repeated augmentation during implantation was required in 7% of cases,

while in the control group, where no preservation was performed at all, augmentation was required in 42% of cases. Accordingly, it turns out that in the case of preservation we need augmentation in 107%, and without it in 42%. “Barone a. Ricci M. Tonelli S. Santini S, Covani U (2013)”

Based on the above, none of the augmentation methods can fully compensate for the resorption of the alveolar ridge. Moreover, implantation is possible no less than 6 months after preservation. During this period, especially in the lower jaw, significant atrophic processes take place in the mucous membrane. The height of the attached gingiva and the degree of keratinization in the area of the alveolar ridge decrease. In addition, after 6 months of waiting, it is often necessary to wait another 3-4 months before osseointegration of the implant, which further increases the loss of both bone tissue and soft tissue. “MA. Atieh, NHM. Alsabeeha, AGT. Payne, S. Ali, CM Jr Faggion, M Esposito. (2021)”, “Barone a. Ricci M. Tonelli S. Santini S, Covani U (2013)”

The time factor is often a big obstacle for patients and doctors themselves, especially in the field of medical tourism, when the maximum result must be achieved in the minimum time.

Considering the period that has passed since the extraction, the following methods of implantation will be selected. Based on the above table, the most difficulties and expected risks are associated with immediate implantation.

However, due to world globalization, which has led to the acceleration of processes, doctors have to offer the patient to complete the treatment in the shortest possible time. Therefore, immediate implantation has become very relevant.

The method of immediate implantation is not universal, just like any other method of treatment, although in specific cases where there are indications for its use, this method is truly irreplaceable.

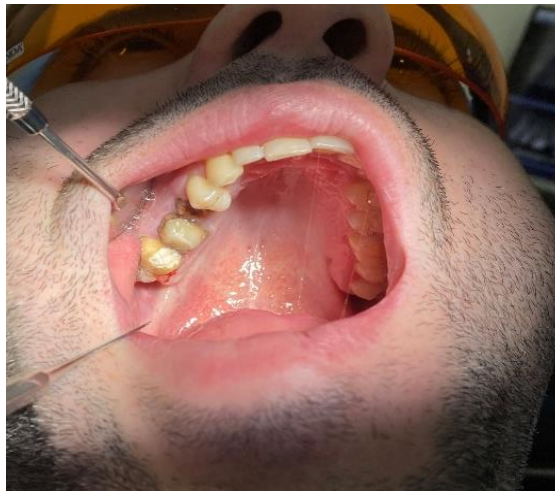**The general and local indications** of immediate implantation are basically the same as those of classical-gold-standard implantation. An essential requirement is the presence of sufficient supporting bone in the periapical space of the socket in order to achieve sufficient primary fixation of the implant.

#### **Contraindications for immediate implantation are:**

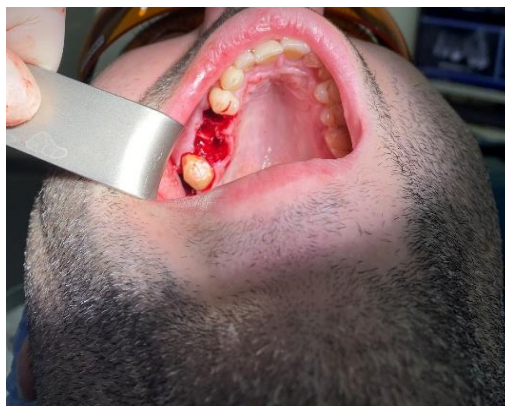1. Presence of acute inflammatory processes in the tissues around the root.
2. Significant destruction of bone tissue around the root.
  - . Molars with joined roots.
4. Low position of the maxillary sinus base, when the distance between the apex of the root and the sinus base is less than 4 mm.
5. Close location of the mandibular canal to the apex of the root.

To carry out immediate implantation, first, it is necessary to make the extraction as safe as possible: (figure1,2,3) not to damage the walls of the socket and the inter-root septum (if it exists). In the case of multi-rooted teeth, root separation is necessary.

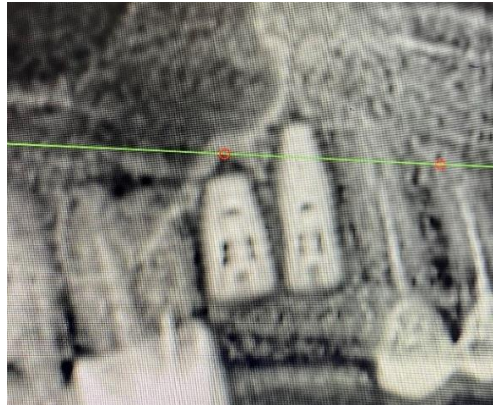
During immediate implantation, the protocol for the formation of the implant socket is different and much more difficult compared to classical implantation. Here we do not have a cortical bone in the alveolar ridge area, so the initial fixation of an implant becomes difficult. In many cases, initial stabilization is simulated -- we may get enough "Torg", but the implant-to-bone contact coefficient (IBC) is quite low, which is the main determinant of osseointegration. Therefore, when the degree of primary fixation of the implant and the IBC coefficient is low, the implant should be closed with a healing screw or a former.



**Figure 1.** Condition before extraction of the teeth



**Figure 2.** After extraction of the teeth



**Figure 3.** Immediate Loading of Dental Implants X-ray

The positioning of the implant, especially in the frontal area, is always done in the direction of the palate. (figure 4,5)

In all cases, the gap between the implant and the socket wall is filled with xenograft, packed with a membrane, and sutured into a cavity.

Based on the above, immediate loading of implants has several advantages compared to other methods:

1. More results in minimal time.
2. Relatively low cost.
3. Maintaining the vertical and horizontal parameters of the bone.
4. Keratinized mucosa is maintained.

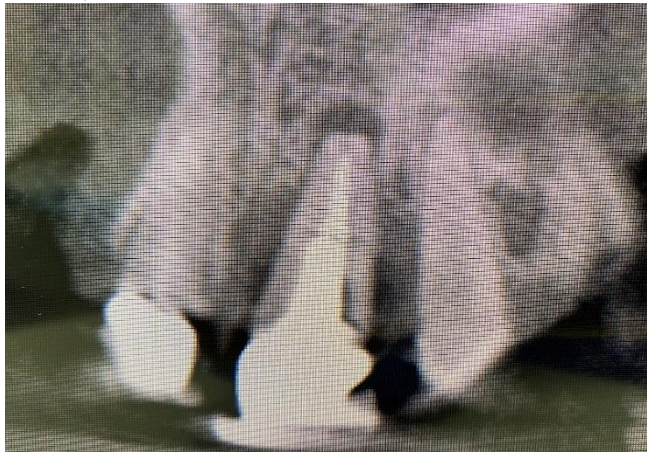### **The results and aim of the research**

The aim of our study was to study the degree of bone and soft tissue remodeling in the alveolar ridge area during immediate implantation with bone augmentation. We used implants of different brands and Xeno bone of different brands. To obtain a perfect result, immediate implantation should be accompanied by a temporary prosthesis, (figure6) however, it is not always feasible to perform immediate implantation, and in some clinical situations the usage of non-removable temporary dentures is impossible. “Journal of Prosthodontics. Volume 17, Issue 7, (October 2008), Pages 576-581”.

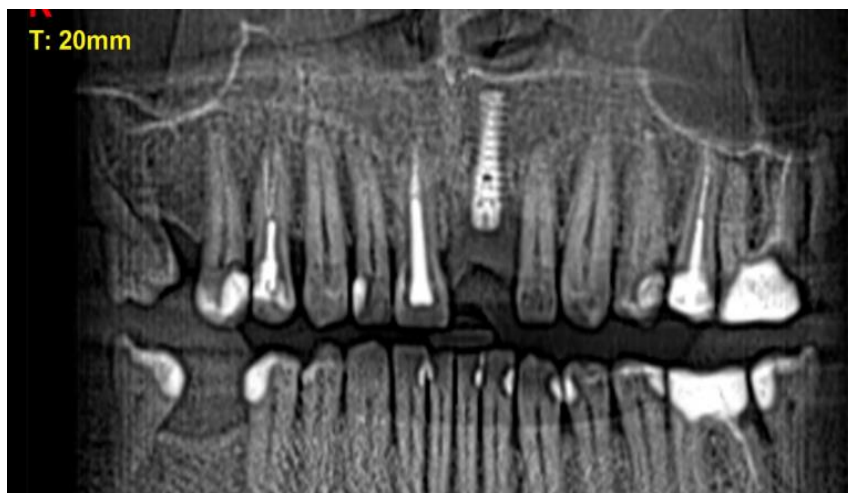#### *Advantages of temporary dentures:*

- Aesthetics.
- Preparation of prosthetic gown, formation of soft tissues.
- Reducing the probability of infection spreading in the implanted area,
- Adaptation to an artificial crown.
- Time savings for the fabrication of a permanent construct after the osseointegration period.

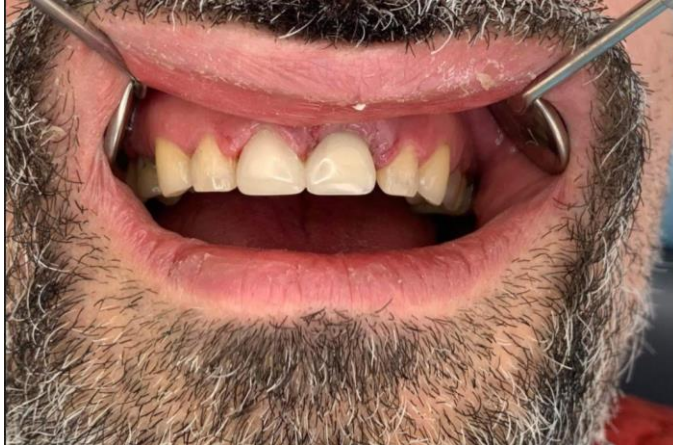The decision about the possibility of non-removable temporary construction is mostly made by the implantologist. If satisfactory initial fixation is achieved, fixation of an artificial construction is allowed.



**Figure 4.** Before Immediate Loading of Dental Implant



**Figure 5** (X-ray After Immediate Loading)



**Figure 6.** Temporary Restoration

There exist direct and indirect prosthetics.

1. In the case of direct prosthetics, the crown is made on a temporary abutment in the clinic and immediately placed in the oral cavity, while in the case of indirect prosthetics, we take an impression, and the construction is made in the technical laboratory. The maximum time of its fixation should be 72 hours. “Natl J Maxillofac Surg. (2015 Jul-Dec)”

In case of impossibility of non-removable construction during immediate implantation, there are other prosthodontic alternative constructions:

- Removable prostheses.
- Maryland Bridge Prosthesis (adhesive bridge prostheses)

### Conclusion

According to our results, immediate loading of dental implants is a method where there's the least amount of loss of marginal bone and gingival keratinization in the alveolar ridge area. Thus, this method does not have an alternative when the necessary conditions for its success are met, and the immediate fixation of prosthodontic constructions makes dental implantation surgery even more successful.

### References:

1. Barone a. Ricci M. Tonelli S. Santini S, Covani U (2013) J periodontal 24;1231-1237. “Tissue changes of extraction sockets in humans: a comparison of spontaneous healing vs ridge preservation with secondary soft tissue healing”.
2. G. Avilo-Ortiz, S. Elangovan, K.W.O. Kramer, D. Blanchette, D.V. Dawson. Department of periodontics The University of

- Lowa 2014. “Effect of alveolar ridge preservation after tooth extraction: A systematic review and meta-analysis”.
3. *Journal of Prosthodontics*. Volume 17, Issue 7, October 2008, Pages 576-581
  4. MA. Atieh, NHM. Alsabeeha, AGT. Payne, S. Ali, CM Jr Faggion, M Esposito. “Interventions for replacing missing teeth: alveolar ridge preservation techniques for dental implant site development.” *Cochrane database of systematic reviews* 2021, issue 4, art No CD010176.
  5. *Natl J Maxillofac Surg.* 2015 Jul-Dec; 6(2): 252–255.doi: 10.4103/0975-5959.183864.
  6. T. Thalmair, S. Fickl, D. Schneider, M. Himze, H. Wachtel, “Dimensional alterations of extraction sites after different alveolar ridge preservation techniques- a volumetric study” 2013.
  7. V. Chappuis, O. Engel, M. Reyes, K. Shahim, L.P. Nolte, D. Buser. *JDR Clinical Research Supplement*, 2013. “Ridge Alterations Post-extraction in the Esthetic zone: A 3D analysis with CBCT”.