

Strangulated Richter's Hernia in an Indirect Inguinal Hernia

Mounir Bouali
Kabira Falousse
Anas El Wassi
Abdelilah El Bakouri
Khalid El Hattabi
Fatima Zahra Bensardi
Abdelaziz Fadil

Department of Visceral Surgical Emergency, Faculty of Medicine and Pharmacy, University Hospital Center Ibn Rochd, Hassan II University, Casablanca, Morocco

[Doi:10.19044/esj.2023.v19n18p113](https://doi.org/10.19044/esj.2023.v19n18p113)

Submitted: 23 March 2023

Accepted: 21 June 2023

Published: 30 June 2023

Copyright 2023 Author(s)

Under Creative Commons BY-NC-ND

4.0 OPEN ACCESS

Cite As:

Bouali M., Falousse K., El Wassi A., El Bakouri A., El Hatabi K, Bensardi F.Z. & Fadil A. (2023). *Strangulated Richter's Hernia in an Indirect Inguinal Hernia*. European Scientific Journal, ESJ, 19 (18), 113. <https://doi.org/10.19044/esj.2023.v19n18p113>

Abstract

Introduction: Richter's hernia is an abdominal hernia in which part of the circumference of the intestine is incarcerated in the hernia sac. Case report: We report a case of Richter's hernia incarcerated through an indirect inguinal hernia. The patient presented with an occlusive syndrome with an imaging appearance of a right inguinal hernial strangulation bowel obstruction. Surgical exploration revealed the presence of an indirect inguinal Richter's hernia with a viable bowel. Discussion: Richter's hernia is a rare hernia of the abdominal wall, it is known by the unusual clinical presentation and the often erroneous late diagnosis that leads to high morbidity and mortality rates. Therefore, with high clinical suspicion, an abdominal CT scan is recommended to establish a prompt diagnosis, as timely surgical intervention is important to reduce mortality. Conclusion: Surgery is the basis of its treatment, but prompt surgical intervention remains. Assessment of bowel viability is an essential part of the repair.

Keywords: Richter hernia, inguinal hernia, Strangulation, Mortality

Introduction

Groin hernias account for 75% of abdominal wall hernias, 95% are inguinal hernias and the remaining 5% are crural hernias. Two-thirds of inguinal hernias are indirect hernias and the rest are direct inguinal hernias. Richter's hernia is characterized by entrapment and strangulation of a circumference of the wall of the bowel loop through a potential hernial defect in the abdominal wall. It is an unusual clinical entity whose clinical course most often leads to a misdiagnosis. (Gupta G. et al., 2021).

Case report

The patient aged 48 years, chronic smoker, never operated, presents with an occlusive syndrome made of material and gas arrest with food vomiting evolving for 3 days, without other associated signs, at a clinical examination the patient was hemodynamically and respiratory stable: blood pressure: 130/60 mmHg, heart rate at 76 bpm, respiratory rate at 20 cpm, normal temperature, on abdominal examination the abdomen was distended and tympanic, the hernial orifices were free, rectal touch without abnormalities, the patient benefited from an abdominal X-ray which showed grelic hydroaeric levels.

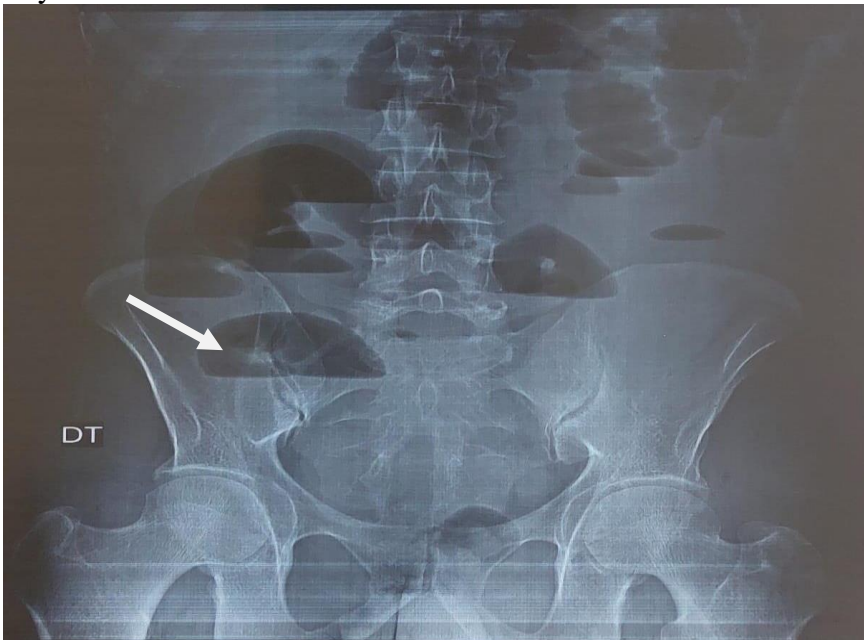


Fig 1. Abdominal x-ray showing dilated small bowel loops with gas-fluid levels

An abdominopelvic CT scan showed the presence of diffuse small bowel distension, with hydroaeric levels, measuring 40 mm in maximum diameter, upstream of a right inguinal transitional level on hernial strangulation of an ileal loop measuring 20x15mm. No parietal enhancement

defect. Absence of pneumoperitoneum. Small peritoneal effusion at the level of the pouch of Douglas. The collapsed appearance of the colonic frame and the last ileal loop.

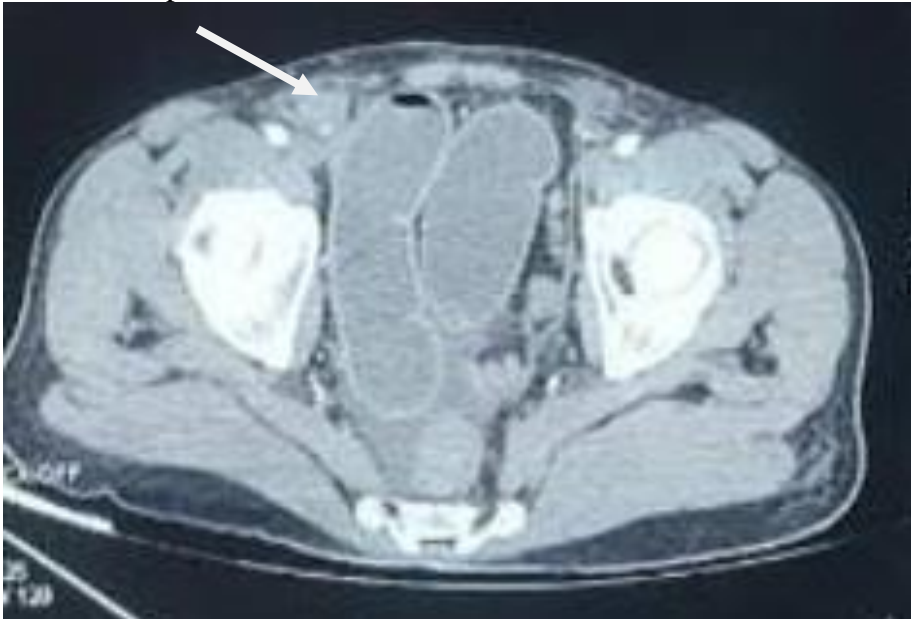

Fig 2. CT scan depicting a bowel loop herniating into inguinal hernia

After optimization of his general condition with a Naso-Gastric tube suction and intravenous fluids resuscitation, it was decided to operate on the patient urgently, under general anesthesia and endotracheal intubation. The patient was approached by a right inguinal incision with the presence of a lateral pinch of an intestinal loop at the level of its antimesenteric edge, realizing an aspect of an inguinal hernia according to Richter. The procedure consisted of a reintroduction of the hernial contents with a cure of the right inguinal hernia according to the BASSINI technique. The outcome was good and the patient was declared discharged on postoperative day 2.

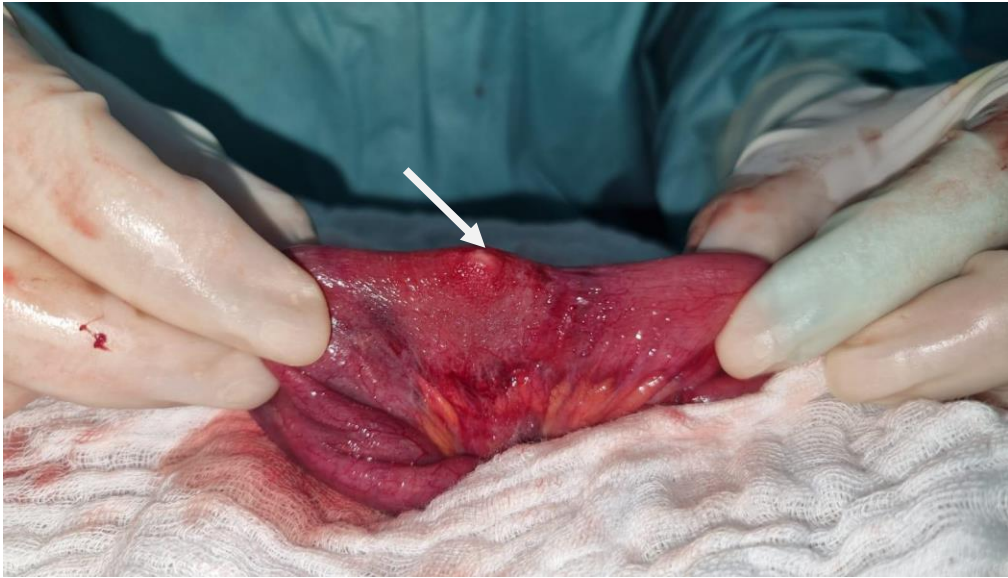


Fig 3 . Aspect of Richter hernia discovered during surgery

Discussion

Richter's hernia was first reported by Fabricius Hildanus in 1598, and August Gottlob Richter gave the first scientific description in 1778 (Agrawal S. et al., 2013; Boughey JC. et al., 2003; Janardhanan Det. Al. 2011).

In Richter's hernia, the antimesenteric edge of the bowel protrudes into the hernial sac but never involves the entire circumference of the bowel. The hernia sac usually contains a segment of the distal ileum, but the entire gastrointestinal tract may be involved, including the stomach, colon, or appendix (Gupta G. et al., 2021; AbuFarha S. et al., 2019).

Richter's hernia can occur at any common hernial site but is most likely to occur in small hernial rings with rigid fascial defects. The most common site is the femoral ring (36%-88%), followed by the inguinal canal (12%-36%) and an abdominal wall incision (4%-25%); however, the least common hernias are umbilical, obturator, suprapubic, spigelic, and gastric, Petit's triangle, sacral foramen, Morgagni, internal, and diaphragmatic hernias. Richter's hernia has also been reported at trocar ports in laparoscopy and also at drainage sites (Gupta G. et al., 2021; Boughey JC. et al., 2003; Goel VK. et al. 2014).

The diagnosis is difficult because the symptoms and clinical course are variable (Floridi A. et al., 2019; Kishi H. et al., 2016). Patients usually do not have intestinal obstruction because the continuity of the bowel is maintained; however, as in our case, intestinal obstruction may occur concomitantly. In addition, the trapped portion of the bowel is often antimesenteric and can rapidly become gangrenous due to limited blood supply. (Murji A. et al., 2017) Therefore, abdominal CT and gastrointestinal

imaging are recommended for prompt diagnosis (Fischer DI. et al., 2020; Hayes C. et al., 2020).

Management is based on surgery. Assessment of bowel viability is important for the therapeutic decision. Richter hernias without signs of necrosis or perforation are treated as uncomplicated hernias. Perforated hernias usually require an exploratory laparotomy to properly treat the affected bowel. (Kang CH. et al., 2014) Diagnostic laparoscopy is an option to evaluate the bowel, accompanied by laparoscopic hernia repair, especially if the affected portion of the bowel is viable. Management consists in avoiding attempts to reduce the contents of the hernia sac, as these must be examined by inspection to verify their viability (Gupta G. et al., 2021).

Conclusion

The high mortality rate associated with Richter hernia can be reduced with early diagnosis and early surgical intervention. A thorough diagnostic approach and careful physical examination are necessary to make an accurate diagnosis. Radiological imaging can be used to confirm the diagnosis and is highly recommended in cases where Richter hernia is suspected. Early surgical intervention is the cornerstone of successful management.

References:

1. Gupta G, Kaur I, Khuroo S, Razdan A, Wani AA. (2021). Unusual Richter's Hernia: Impacted foreign body leading to incarceration and perforation - A rare clinical entity. *Int J Surg Case Rep*,79:492-5.
2. Agrawal S, Daruwala C. Richter's hernia.(2013). *Clinical Imaging*. 1,37(3):593-4.
3. Boughey JC, Nottingham JM, Walls AC.(2003). Richter's hernia in the laparoscopic era: four case reports and review of the literature. *Surg Laparosc Endosc Percutan Tech*,13(1):55-8.
4. Janardhanan D, Martis JJS, Rajeshwara KV, Shridhar MK, Sudarshan S.(2011). Strangulated Richter's Umbilical Hernia - A Case Report. *Indian J Surg*,73(6):455-7.
5. AbuFarha S, Chorti A, Michalopoulos A, Papavramidis TS.(2019). Richter's hernia in a 5-mm trocar site. *SAGE Open Med Case Rep*,7:2050313X18823413.
6. Goel VK, Gupta AK, Masood S, Pandey A.(2014). Richter's hernia after an intraperitoneal mesh repair. *Asian J Endosc Surg*,7(4):330-3.
7. Floridi A, Giuliani D, Magnoli M, Monti M, Segalini E.(2019).Laparoscopic treatment for an inguinal Richter's hernia: an unusual indication in case of acute small bowel obstruction. *ANZ J Surg*,89(10):E470-1.

8. Kishi H, Kodama M, Murano S, Toyoda A, Yonekura S.(2016). Richter's Type of Incarcerated Obturator Hernia that Presented with a Deep Femoral Abscess: An Autopsy Case Report. *Am J Case Rep*,17:830-3.
9. Murji A, De Gasperis-Brigante C, Leyland N.(2017). Richter's Hernia After Laparoscopic Surgery. *J Minim Invasive Gynecol*,24(4):518-9.
10. Fischer DI, Perry ZH, Rivin M.(2020). A Port Site Richter's Hernia. *Am Surg*,3134820979186.
11. Hayes C, Ivanovski I, Neduchelyn Y, Schmidt K .(2020). Obturator hernia of Richter type: a diagnostic dilemma. *BMJ Case Rep*,13(12):e238252.
12. Kang CH, Tsai CY.(2014). Richter's femoral hernia manifested by a progressive ileus. *Formosan Journal of Surgery*,47(5):193-6.