

SUDDEN DEATH FROM VAGAL INHIBITION

Bledar Xhemali, MSc.

Zija Ismaili, MSc.

Linda Matua, MSc.

Mirnela Cinije, MSc.

Institute of Forensic Medicine, Tirana

Abstract

This paper will discuss and evaluate the alternative explanations of a sudden death due to the vagal inhibition caused from the application of a mild pressure to the neck. The death – not as a phenomenon, but as an „event“ caused by and related to several factors and circumstances – has a legal, medical and even social interest, whether its cause was natural or unnatural. The more unpredictably and faster a death occurs the more difficult the identification of its cause appears, especially in cases of trauma and of any present known or unknown, or even hidden, pathology.

In this paper we will discuss a casus of a 27 year old male who died almost immediately after a pressure was applied to the neck. Necropsy examination showed some irregular light blue-red colored bruises on the neck region, which were caused by the fist. After the incision of the neck's region, the bruises revealed a tissue crush and infiltrating hemorrhages involving all layers of the skin and the tissue.

Keywords: Sudden death, minor trauma, reflective death, vagal inhibition

Introduction

In this paper we discuss and evaluate the alternative explanations of a sudden death due to the vagal inhibition caused from a minor trauma. We present a case report that answers the main question: was the death caused from any preexisting illness or pathology or should the trauma be expelled as cause of death, if there were no predispositions from a pathological state?

Since the very day when the truths and the scientific knowledge of Medicine were *functionalized* by the needs of justice administration organs, the definition of the cause of death has become the catchphrase, a ubiquitous topic within the routine practice of Forensic Medicine. The work of the forensic expert does not consist in *finding* out *one* among some possible causes of death, but in *defining* the *very cause* of it and the

pathophysiological mechanism(s) involved. The definition of the cause of death and of the mechanism(s) involved is a necessary and unavoidable challenging enterprise due to both the causal and morphological plurality of death. Regarded as a phenomenon *per se*, death is essentially, and always, one and the same; what makes different the death of a person from that of another, it is not the death *as such*, i.e., the mere ending of the *livingness*, but the cause and the mechanism(s) that provoke and made inevitable the end of the livingness. In this respect, Forensic Medicine does not study the death as such, but the way in which it takes place. In the Forensic Medicine practice, the nature of death means precisely the nature of this “way”, the nature of death’s appearance. These very aims make Forensic Medicine unique, for it “reads” death both as *quasi liber et pictura* and as *ut pictura poiesis*. These *interpretative* and *methodological* perspectives are highly important and essentially interconnected. The definition of the cause of death and the mechanism(s) involved should be treated somehow monolithically, *en bloc*, for it is precisely from this very approach that the nature of the appearance of death is determined. Sometimes the cause of death is visible, as in the cases of head and brain injuries; but it is still insufficient to determine the very nature of death, the differential diagnosis. In such cases, the cause of death is a “necessary condition”, but not a “sufficient” one. To determine the nature of death, the expert ought to look closely at the mechanism(s) involved, as well as to the nature of the violence factors (*Michalomidimitrakis* 2004). This is what makes Forensic Medicine a challenging practice.

The case we are to report shows it very eloquently: E. C., 27 years old, was driving with two other friends near an open-air restaurant in which a wedding lunch was taking place. After having driven madly several times up and down, causing noise and powdering a huge amount of dust, Sh.D., the brother of the bride, went out and told him to stop. The other did not agree. After some violent wordy debate through the car window, A. B. stroked the other with fist from outside of the car, and the other died almost immediately. The corpse was brought to Forensic Institute for the eventual medico-legal examination. Necropsy examination showed some irregular bruises on the neck, light blue-red colored, which were caused by the fist. After incision of neck’s region, the bruises reveals tissue crush and infiltrating hemorrhage involving all layers of the skin and the tissue. The application of pressure to the neck can result in death due to asphyxia, but rare instances have been reported of mild or ‘playful’ pressure being applied to the neck that have resulted in ‘instantaneous death’. Traditionally these ‘freak accidents’ have been ascribed to ‘vagal inhibition’ or ‘reflex cardiac arrest’, involving stimulation of the carotid sinuses. More recently, was proposed mechanisms for asphyxial deaths, including mechanisms of sudden death during the application of pressure to the neck (*Purdue* 2000).

Materials and Methods

Pathological data: From the external examination, there were noticed some little and superficial injuries on the eyebrow region, which were by the bumping up of the head against the steering wheel, and some irregular bruises on the neck (above the level of the carotid sinus), light blue-red colored, which were caused by the fist.

The autopsy revealed general signs of asphyxia, dark colored and liquid blood, venous stasis of the organs the brain was very little edematous, and it contained neither traumatic nor hemorrhagic or pathological lesions. The incisions of neck's region bruises reveals tissue crush and infiltrating hemorrhage involving all layers of the skin and the tissues.

There were hemorrhagic infiltrations dark red colored in the region where the ecchymoses were present. The hyoid ribs were intact. In fact the microscopic examination revealed hemorrhage infiltration of all layers of the skin and tissue (ref. fig.1 and fig. 2).

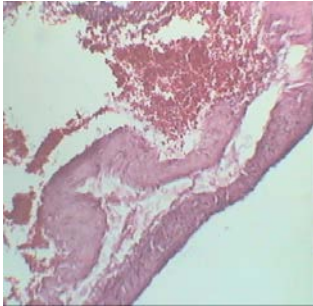


Fig.1

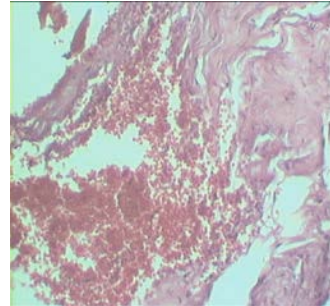


Fig.2

Also the microscopic examination of heart revealed a light interstitial aedema, the muscular fibers were undulated (ref. fig 3 and fig. 4)

Microscopic diagnosis: ventricular fibrillation.

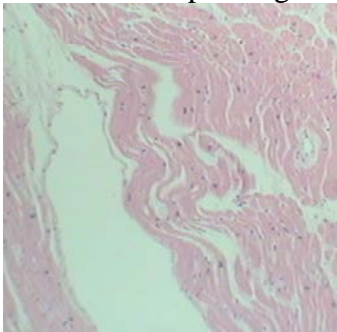


Fig.3

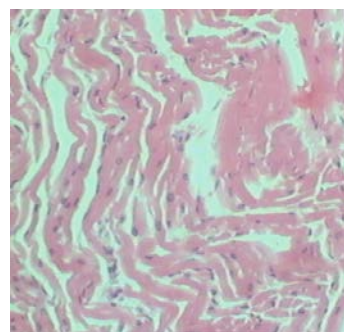


Fig.4

The toxicological data: During the autopsy were taken blood samples for toxicological purposes. These samples were taken to the laboratory of toxicology and analyzed for drugs (opiates) and ethylic alcohol.

Thin layer chromatography was used to screen the blood sample for opiate metabolites. (All reagents used are GC and HPLC grade Merck). A GC – HS Shimadzu QP 2010 was used to determinate the concentration of ethylic alcohol. The blood sample resulted positive for metabolites of opiates monoacetylmorphine, and negative to the analysis for ethylic alcohol.

Discussion

The death – not as a phenomenon, but as an „event“ caused by and related to several factors and circumstances – has a legal, medical and even social interest, whether its cause was natural or unnatural. The more unpredictably and faster a death occurs the more difficult the identification of its cause appears, especially in cases of trauma and of any present known or unknown, or even hidden, pathology. The case above has lots of dilemmas which need to be resolved:

- 1- Is it possible the trauma to be totally responsible or independently responsible for the caused death?
- 2- Did the trauma contribute to the speed of death?
- 3- Was the death caused from any preexisting illness or pathology or should the trauma be expelled as cause of death, if there were no predispositions from a pathological state?

The third point is the most interesting and difficult one, because the certainty of the cause of death can be rather suspicious. The naïve judgment to invent a cause of death is really harmful.

It would be better to call the case as a blank autopsy, if there were no indications from the case history, or the autopsy findings or the toxicological data, than to speculate with nonsense diagnostic. It is not common but there are cases in medico legal investigation when happens a physical confrontations, even with the total autopsy, accessorized with the microscopic, toxicological, microbiological and biological examination, still the determination of cause of death isn't clear and still controversial. In these cases the confrontation hasn't been that aggressive and in the victim body there are no signs of violence or the grade of injuries isn't that high, so that the death explanation from violence is not very clear (*Meksi S. 2005*). The situation is complicated when the victim has been under stress, psychological disorders, drug addiction or inebriety state. The immediate and sudden death that can occur during a psycho – physical confrontation between two persons and during the autopsy the signs are really insignificant to believe that the nature of death is violent one can be explained based on two phys – pathological mechanism (*Hirsch CS, Adams VI*).

The first one is the neuro – hormonal, where the victim involved in a psycho – physical confrontation, reflects an irritated emotive state and if it is under drug substances or in inebriety state, in his body happens an

immediate release in the blood stream of catecholamine, mostly epinephrine and nor-epinephrine hormones. These hormones act in the heart by increasing the heart beat, by increasing the contraction force of the myocardium, increasing the velocity of the impulses and so happen the increment of arterial pressure (*Standring 2005*). As consequence of all this it is increased the heart muscles demand for oxygen these accompanied with a oxygen hunger causing a focal ischemia of myocardium followed by a lethal cardiac arrhythmia.

The second mechanism involves death from inhibition, this occurs instantly within seconds or at most 2 minutes after a minor trauma. This mechanism is similar to our case, because it is about minor traumas of the neck structures as result of use of a substantial force pressure like the fist pressure. Sometimes strikes or neck strangulations can bring death even with the use of a moderate force (*Simpson K*). If during body examination small changes have been seen in the neck region, it is better to give a careful opinion regarding the used strength intensity. External signs should be investigate with caution, coordinating them with the internal signs. In our case from the toxicological examination in the blood sample was detected opiates metabolite monoacetilmorphine, which actually exclude the cause of death from overdose (*Clinical Toxicology B.Preza*). The presence of heroine metabolite in blood leads to an increment of reflector sensitivity of the carotid sinus in front of excitations.

Novel terms are utilised in an attempt to explain the pathophysiological mechanisms involved, which describe a spectrum of insults leading to cardiac dysfunction;

- Remotely Stimulated Cardiac Dysfunction (RSCD)
- Cumulative Cardiac Insult (CCI) and
- Instantaneous Neurogenic Cardiac Arrest (INCA)
- Pressure on the neck during, for example manual strangulation would incorporate elements of neural and humoral mechanisms together with hypoxic changes to bring about CCI and death.

It is suggested that prolonged pressure on the carotid arteries below the level of the carotid sinuses could bring about sympathetic discharge, increasing the risk of ectopic beats and VF (particularly in the setting of fear).

Pressure above the level of the sinuses (or on them) would result in parasympathetic discharge and potentially a-systole in those with sensitive bar-receptors (*Sunthareswaran*).

Without elements of asphyxia and prolonged compression, the concept of INCA is proposed, which represents the extreme end of CCI spectrum and involves an overwhelming parasympathetic discharge from highly sensitive carotid sinuses.

Conclusions

In this case there is a severe damage of the neck structures, which shows the use of a considerable amount of force and indicates the intent to injure. Sometimes deliberate interference with the neck structures can kill without producing much damage. If only slight changes are seen in the neck structures, a guarded opinion should be given about the probable degree of the force used. The very few remains of heroin (monoacetylmorphine) found in blood, excluded the death by overdose. Pressure above the level of the carotid sinus would result in parasympathetic discharge and potentially asystole in those with sensitive baroreceptors. In our case the mechanism of death was Instantaneous Neurogenic Cardiac Arrest. Sudden instant death can occur from the traumatic vagal excitation of the neck that may happen in drug addicted subjects or dipsomaniac subject through the high sensitivity of baro-receptors of carotid sinus where the lethal fibrillation is settled (*Simpson*).

The forensic diagnosis is determined by evaluating:

- The tissues injuries of the neck, even small ones
- The exclusion of any other cause of violence, and this can be done thorough a professional complete and accurate autopsy.
- The toxicological and histological pathological examination. Usually screening for drugs and alcohol determination should be performed; also the histological pathological examination for all internals especially of the myocardium should be performed.
- The death circumstances or even the history of victim's life (drug abusing or alcohol abusing).

From the judicial point of view these kind of death should been considered as unfortunate cases, because the author using a moderate force, objectively couldn't predict that this would lead to a lethal consequence.

References:

- Michalomdimitrakis M. – Iatrodikastikue , Athens 1997
Berne RM, Levy MN. Principles of Physiology (2nd Ed). Mosby 1996
Cohen MV. American Heart Journal 1972; 84(5):681-686
Meksi.S, Death from violence 2005
Clinical Toxicology B.Preza, L.Preza; 404-406
Hirsch CS, Adams VI. Sudden and unexpected death from natural causes in adults. Chapters 5 and 6 In: 'Spitz and Fisher's Medicolegal investigation of death. Guidelines for the application of pathology to crime investigation.' Spitz WU (Ed) (3rd Ed) 1993 Charles C Thomas Publishing, Springfield Illinois, USA
Purdue BN. Asphyxial and related deaths. Chapter 15. In: The Pathology of Trauma. Ed Mason JK, Purdue BN. 2000 Arnold Publishing, London UK

Schwartz PJ, Vanoli E, Stramba-Badiale M et al. *Circulation* 1988; 78: 969-979

Simpson K. Deaths from vagal inhibition. *Lancet* 1949 558-560

Standring S. (Ed). *Gray's Anatomy*. 39th Ed. 2005 Elsevier, London UK

Sunthareswaran R. *Cardiovascular System*. Mosby's Crash Course. 1998 Mosby, London UK

Willich SN, Maclure M, Mittleman M et al. *Circulation* 1993 87(5):1442-1450