

PARASITIC INFECTIONS OF THE COMMON CARP *Cyprinus carpio* FROM LESSER ZAB RIVER IN KURDISTAN REGION, IRAQ

Kamaran S. Mama

Shamall M. A. Abdullah

Dep. Biology, Coll. Education, Univ. Salahaddin, Erbil, Iraq

Abstract

A total of 150 common carp *Cyprinus carpio* were collected from Lesser Zab river, near Alton Kupri, south of Erbil city, Kurdistan region, Iraq, during the period from August 2010 until the end of May 2011. The fishes were examined for ecto- and endoparasites. The study revealed the existence of nine species of parasites. These included two species of protozoans (*Ichthyophthirius multifiliis* and *Trichodina reticulata*), four species of monogeneans (*Gyrodactylus baikalensis*, *G. elegans*, *G. gobioninum* and *G. vicinus*), one species of each of trematode (*Diplostomum spathaceum*), cestode (*Bothriocephalus acheilognathi*) and crustacean (*Lernaea cyprinacea*). The record of *G. gobioninum* in the present study is considered as the first record in Iraq, and *T. reticulata* and *G. baikalensis* in Kurdistan region. Also, *C. carpio* is regarded as a new host for *T. reticulata* in Iraq.

Keywords: Common carp, Parasite, Lesser zab river, Kurdistan region, Iraq. received

Introduction

The common carp *Cyprinus carpio* Linnaeus, 1758 belong to Order Cypriniformes, Family Cyprinidae (Froese and Pauly, 2011). This fishes was introduced for the first time into Iraq in 1955 from Holland and Indonesia into Al- Zaaferaniya fish farm at Baghdad city (Hamed, 1960). In Kurdistan region, the first batch of these fishes was cultured in Dokan lake in 1967. As recently as 2004, two million fingerlings of this species were distributed by FAO to the Dokan hatchery to enhance production, and now spread to many farms in the region (Coad, 2010).

Due to common carp's adaptation to a wide range of climatic and geographical condition, many of parasites have been found in wild and domestic carp (Tekin-Özan *et al.*, 2008). As a result of the development of carp culture industry and the high prevalence of this species in all main rivers, lakes and marshes In Iraq, the parasites of *C. carpio* had a great deal and much attracted the attention of biologists (Mhaisen, 1993). The importance of fish parasites is directly related to the importance of the fishes that they may infect and result in different types of injuries and damages (Amlacher, 1970).

The present paper is the second part of a large scale study concerning with the parasites infected *C. carpio* from Lesser Zab river in Kurdistan region, Iraq.

Materials and Methods

A total of 150 *C. carpio* were collected from Lesser Zab river near Alton Kupri town in the north-east of Iraq, between latitudes 34°-36° south to north and longitude 43°-46° west to the east, 45 km south of Erbil city. The fish were collected by fishermen by using cast net and gill nets, during the period from August, 2010 until the end of June 2011. Fish were transported a live in a cool box with pond or local river water to the laboratory of parasitology, College of Education/ Scientific Departments, of Biology, University of Salahaddin. The fishes were identified according to Froese and Pauly (2011).

In the laboratory, the fishes were examined externally and internally for parasites. Skin, fins, gills and buccal cavity smear were prepared by slight scraping and examined under a light compound microscope. Whole eyes were removed then the lens was dissected and removed from each eye then inspected under dissecting microscope for parasites. For the study of the internal parasites, the fishes were dissected from the ventral side. The body cavity, stomach, intestine, spleen, liver, kidneys, heart, muscles, swim bladder and gonads were separated and examined carefully under a dissecting microscope for the presence of parasites or cysts (Amlacher, 1970).

Methods used for collecting, fixing, staining and mounting of the parasite specimens were as follows:

Protozoa: For the study of the protozoan, most of them were identified in a direct way without any technique, by preparing smears of mucus which was scraped from the skin, fins and gills, onto a slide and spreaded carefully with a cover slip and examined, then important measurement were taken for each protozoan.

Monogenea: Skin, fins and gills smears were prepared and microscopically examined. Care was taken to isolate and flatten the specimens, which were then stained with aqueous neutral red and permanent slides were prepared with glycerin-gelatin (Kritsky *et al.*, 2004).

Digenea and Cestoda: Live worms were washed in 0.6% saline solution and fixed in 5% hot formalin, stained with haematoxylin or acetocarmine, then cleared in xylene and mounted in Canada balsam (Scholz, 1989).

Crustacea: Specimens were cleared with 85% lactic acid, and permanent slides were prepared by using jelly glycerin (Kim, 2004).

Photos were taken with Sony Syber Shot Digital camera model DSC-T9, 7.2 mega pixels. The figures were drawn by using a Camera Lucida (Drawing tube). Measurements of parasite were made with an Olympus ocular micrometer. The detected parasites were identified according to their morphology. Parasites were identified according to Bykhovskaya-Pavlovskaya *et al.* (1962), Gussev (1985) and Pugachev *et al.* (2010).

Results and Discussion

A total of 150 common carp *C. carpio* were collected and inspected for parasites from Lesser Zab river. The present study showed the existence of nine species of parasites including two species of protozoans (*Ichthyophthirius multifiliis* and *Trichodina reticulata*), three species of monogenetic trematodes (*Gyrodactylus baikalensis*, *G. elegans*, *G. gobioninum* and *G. vicinus*), one species of each of metacercariae of digenetic trematode (*Diplostomum spathaceum*), cestode (*Bothriocephalus acheilognathi*), and crustacean (*Lernaea cyprinacea*). The distribution of the parasites, their location on or in the fish host body, the prevalence and mean intensity of infection are summarized in Table (1). The following is an account on the description and measurements of these parasites, especially those which were recorded for the first time in Kurdistan region and in Iraq:

***Ichthyophthirius multifiliis* Fauquet, 1876**

This ciliated protozoan was found on the skin, fins and gills of *C. carpio* with prevalence of 2.66%, (Table 1). This parasite has been reported for the first time in Iraq from *Mugil dussmien* (Herzog, 1969). After that, it was reported from 23 different fish hosts including *C. carpio* (Mhaisen, 2012). In Kurdistan region, it was reported from different species from Darbandikhan lake, Lesser Zab river, Greater Zab river and Ainkawa fish hatchery (Abdullah, 2005; Abdullah and Mhaisen, 2006; Al-Marjan and Abdullah 2009).

***Trichodina reticulata* Hirschmann et Partsch, 1955**

This ciliated protozoan was isolated from the skin and fins of *C. carpio* with prevalence of 3.33% (Table 1). Medium to large disc-shaped trichodinid diameter of body 55-70 μm , adhesive disc 48-55 μm in diameter, denticle ring 30-38 μm . Number of denticles 22-26. Inner margin of denticle blade curved and roughly angular on outside margin, with squared distal end, length of blade 6-7 μm . Central part oblong, with oblong to rounded overlapping end. Projection of central part is invisible. Ray with little taper, tip blunt to square; length of ray 5-7 μm . Length of span 14-16 μm (**Fig. 1**).

This parasite was recorded for the first time in Iraq by Jori (2006) on the gills of *Silurus triostegus* from Al-Hammar marshes in Basrah city. No more hosts are known for this species in Iraq. So, *C. carpio* is now considered a new host for this ciliated protozoan in Iraq and the present study represents the first record of *T. reticulata* in Kurdistan region.

***Gyrodactylus baikalensis* Bogolepova, 1950**

This species was recovered from the skin of *C. carpio* with a prevalence of 3.33% (Table 1). Small, elongated worms. Body length 0.40-0.62 mm and width 0.13-0.20 mm. The anterior end of the body bilobed and each lobe has a head organ. Eye spots are absent. The anterior end of the body bilobed and each lobe has a head organ. Eye spots are absent. The haptor armament consists of 16 hooklets and two median hooks without outer roots but with two bars (ventral bar with a membrane and a dorsal bar). Total length of hooklets 0.028-0.032 mm. Total length of median hooks 0.06-0.07

mm, main part 0.047 mm, point 0.032 mm. Size of ventral bar 0.006-0.008 X 0.025-0.028 mm, membrane 0.005-0.008 mm. Size of dorsal bar 0.002 X 0.015-0.018 mm (Fig. 2).

The parasite was recorded for the first time in Iraq from the same host from Suwairah and Latifiyah (Salih *et al.*, 1988). After that, it was reported from eight different fish hosts (Mhaisen, 2012), but there are no any previous records for *G. baikalensis* in Kurdistan region.

***Gyrodactylus elegans* Nordmann, 1832**

This trematode was found on skin and gills of *C. carpio* with a prevalence of 2% (Table 1). This species was reported for the first time in Iraq on the skin *C. carpio* and *Liza abu* from Al-Zaafarany fish farm (Ali and Shaaban, 1984). After that, it was reported on 22 fish species in Iraq (Mhaisen, 2012). Also, it was reported on *C. carpio* from Lesser Zab river, Darbandikhan lake and Ainkawa fish hatchery in Kurdistan region (Abdullah and Mhaisen, 2004; Abdullah, 2005; Al-Marjan and Abdullah, 2009) respectively.

***Gyrodactylus gobioninum* Gussev, 1955**

This parasite was found on the skin of *C. carpio* with a prevalence of 1.33% (Table 1). Small worms. Body length 0.30-0.35 mm and width 0.05-0.09 mm. Length of hooklets 0.022-0.025 mm. Total length of median hooks 0.047-0.050 mm, main part 0.037 mm, point 0.026 mm, inner root 0.016 mm. Size of ventral bar 0.005-0.006 X 0.015-0.017 mm, membrane 0.009-0.014 mm. Size of dorsal bar 0.002 X 0.015-0.017 mm (Fig. 3).

The present specimen agreed very well with Pugachev *et al.* (2010) specimens except that the present parasite is larger, besides it was detected from a different fish host (*C. carpio*). While, Pugachev *et al.* (2010) found it on the fins of *Gobio gobio*, *Romanogobio albipinnatus* and *Abbottina rivularis* in the Danube, Elbe, Older rivers and lake Khanka. Since no previous report about recording of this species is available in Iraq, the present record represents the first record of *G. gobioninum* in Iraq.

***Gyrodactylus vicinus* Bykhovskii, 1957**

This trematode was detected on the skin and gills of *C. carpio* with a prevalence of 4.66% (Table 1). Previously, *G. vicinus* was reported in Iraq on the skin of *C. carpio* from Al-furat fish farm in Babylon province and Lesser Zab river in Kurdistan region (Al-Zubaidy, 1998; Abdullah and Mhaisen, 2004). The present monogenetic trematodes are greatly in accordance with the specimens which were recorded previously in Iraq.

***Diplostomum spathaceum* (Rud., 1819)**

This metacercariae was found in the eye lens of *C. carpio* with a prevalence of 1.33% (Table 1). Abdullah (1990), who recorded *D. spathaceum* for the first time in Iraq from eye lens of *B. luteus*, *C. macrostomum* and *C. carpio* from Dokan Lake. According to Mhaisen (2012) a total of 26 fish host species were so far known for *D. spathaceum* in Iraq.

***Bothriocephalus acheilognathi* Yamaguti, 1934**

Many specimens of larvae and adults of this cestode were found in intestine of *C. carpio* with a prevalence of 2% (Table 1). This parasite was recorded for the first time in Iraq by Khalifa (1982) from *C. carpio* in some fish farms in Baghdad. Later, it was reported from 19 fish hosts in Iraq (Mhaisen, 2012).

***Lernaea cyprinacea* Linnaeus, 1758**

This crustacean was found on the skin and gills of *C. carpio* with prevalence of 2.66% (Table 1). The anchor worm was firstly recorded in Iraq on seven fish species in Al-Zaafarany fish farm south of Baghdad (Al-Hamed and Hermiz, 1973). Later, it was reported from 24 fish host species from many fish farms as well as from many inland water bodies in Iraq (Mhaisen, 2012). In Kurdistan region, it was reported from five species of fishes namely: *Barbus barbulus*, *B. grypus*, *B. luteus*, *Cyprinus carpio* and *Leuciscus Lepidus* from Dokan, Darbandikhan lakes and Ainkawa fish hatchery (Abdullah, 1990; 2005; Al-Margan, 2007).

References:

- Abdullah, S. M. A. (1990). Survey of the parasites of fishes from Dokan lake. M. Sc. Thesis, Coll. Sci., Univ. Salahaddin: 115pp. (In Arabic).
- Abdullah, S. M. A. (2005). Parasitic fauna of some freshwater fishes from Darbandikhan lake, North of Iraq. J. Dohuk Univ., 8(1): 29-35.

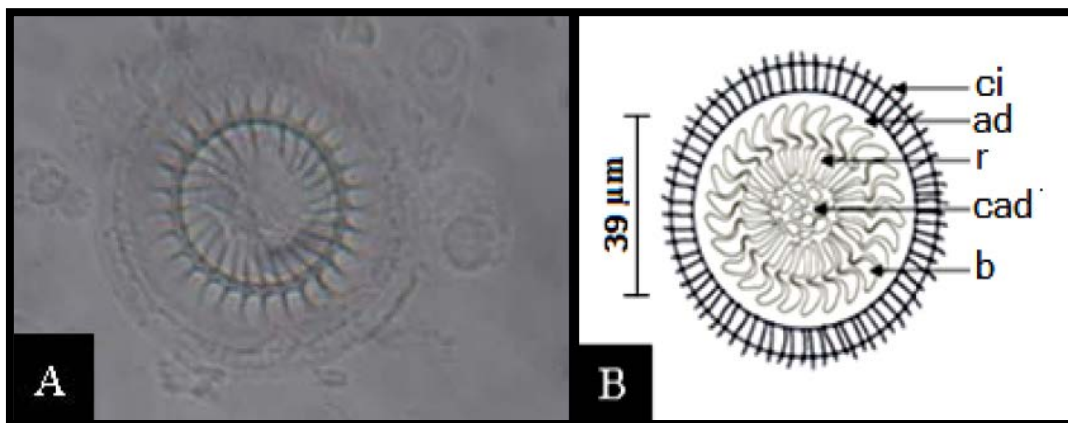
- Abdullah, S. M. A. and Mhaisen, F. T. (2004). Parasitic infections with Monogenetic trematodes on fishes of Lesser Zab and Greater Zab Rivers in northern Iraq. *Zanco*, 16(4): 43-52.
- Abdullah, S. M. A. and Mhaisen, F. T. (2006). Parasitic infections with Protozoa and Crustacea on fishes of Lesser Zab and Greater Zab rivers, north of Iraq. *Proc. 4th Sci. Conf. Coll. Vet. Med., Univ. Mosul / 20-21 September 2006*, 1: 51-58.
- Al-Hamid, M. I. and Hermiz, I. (1973). Experiments on the control of anchor worm (*Lernaea cyprinacea*). *Aquaculture*, 2: 45-51.
- Ali, M. D. and Shaaban, F. (1984). Some species of parasites of freshwater fish raised in ponds and Tigris-Al-Tharthar canal region. *Seventh Sci. Conf., Iraqi Vet. Med. Ass., Mosul. (Abstract)*.
- Al-Margan, K. S. N. (2007). Some ectoparasites of the common carp (*Cyprinus carpio*) with experimental study of the life cycle of the anchor worm (*Lernaea cyprinacea*) in Ainkawa fish hatchery, Erbil province. *M. Sc. Thesis, Sci. Educ. Coll., Univ. Salahaddin*: 99pp.
- Al-Marjan, K. S. N. and Abdullah, S. M. A. (2009). Some ectoparasites of the common carp (*Cyprinus carpio*) in Ainkawa fish hatchery, Erbil province. *Duhok, J. Duhok Univ. (Special Issue)*, 14(1): 102-107.
- Al-Zubaidy, A. B. (1998). Studies on the parasitic fauna of carps in Al-Furat fish farm, Babylon province, Iraq. *Ph. D. Thesis, Coll. Sci., Univ. Babylon*: 141pp. (In Arabic).
- Amlacher, E. (1970). *Textbook of fish diseases (Engl. Transl.)*. T. F. H. Publ., Jersey city: 302pp.
- Bykhovskaya-Pavlovskaya, I. E.; Gusev, A. V.; Dubinia, M. N.; Izyumova, N. A.; Smirnova, T. S.; Sokolovskaya, I. L.; Shtein, G. A.; Shul'man, S. S. and Epshtein, V. M. (1962). *Key to parasites of freshwater fish of the U. S. S. R. Akad. Nauk, S. S. S. R., Moscow*: 727pp. (In Russian).
- Coad, B. W. (2010). *Freshwater fishes of Iraq*. Pensoft Publisher, Sofia: 275 pp+ 16 plates.
- Froese, R. and Pauly, D. (2011). *FishBase. World web electronic publication. www.fishbase.org, version (2/2011)*.
- Pugachev, O. N.; Gerasev, P. I.; Gussev, A. V.; Ergens, R. and Khotenowsky, I. (2010). *Guide to monogenoidea of freshwater fish of Palaearctic and Amur regions. Ledizioni Ledipublishing, Milano*: 567pp.
- Gussev, A. V. (1985). Parasitic metazoans: Class Monogenea. In: Bauer, O. N. (Ed.). *Key to the parasites of freshwater fish fauna of the U.S.S.R. Nauka, Leningrad*, 2: 1-424. (In Russian).
- Hamed, M. I. (1960). *Carp culture in Iraq. Iraqi J. Agric. Sci.*, 1(2):14-23. (In Arabic).
- Herzog, P. H. (1969). *Untersuchungen über die parasiten der süßwasserfische des Irak. Arch. Fischereiwiss.*, 20(2/ 3): 132-147.
- Jori, M. M. (2006). Parasitic study on the asian catfish *Silurus triostegus* (Heckel, 1843) from Al-Hammar marshes, Basrah, Iraq. *M. Sc. Thesis, Coll. Educ., Univ. Basrah*: 192pp.
- Khalifa, K. A. (1982). Occurrence of parasitic infection in Iraqi an fish ponds. *Second Arab. Conf. Biol. Sci., Arab Biol. Union Fes. 17-20 March, 1982 (Abstract)*.
- Kim, I. H. (2004). Copepodid stages of *Ergasilus hyponesi* Yamaguti, (Copepoda, Poecilostomatoida, Ergasilidae) from a brackish lake in Korea. *Kor. J. Biol. Sci.*, 8: 1-2.
- Kritsky, D. C.; Panndey, K. C.; Agrawal, N. and Abdullah, S. M. A. (2004). Monogenoids from the gills of spiny eels (Teleostei: Mastacembelidae) in India and Iraq, proposal of *Mastacembelocleidus* gen. n., and status of the Indian species of *Actinocleidus*, *Urocleidus* and *Haplocleidus* (Monogenoidea: Dactylogyridae). *Folia Parasitol.*, 51: 291-298.
- Mhaisen, F. T. (1993). A review on the parasites and diseases in fishes of ponds and farms of Iraq. *Iraqi J. Vet. Sci.*, 6(2): 20-27. (In Arabic).
- Mhaisen, F. T. (2012). *Index-catalogue of parasites and disease agents of fishes of Iraq, Unpubl. (Personal communication)*.
- Salih, N. E.; Ali, N. M. and Abdul-Ameer, K. N. (1988). Helminthic fauna of three species of carp raised in ponds in Iraq. *J. Biol. Sci. Res.*, 19(2): 369-386.
- Scholz, T. (1989). Amphilinida and Cestoda, parasites of fish in Czechoslovakia. *Acta Sci. Nat. Brno.*, 23(4): 1-56.
- Tekin-Özan, S.; Kir, İ. and Barlas, M. (2008). Helminth parasites of common carp (*Cyprinus carpio* L., 1758) in Beyşehir lake and population dynamics related to month and host size. *Turk. J. Fish. Aquat. Sci.*, 8: 201-205.

Table (1): The distribution of parasites on the gills of *C. carpio* (150) from Lesser Zab river.

Parasites	No. of infected fish	Prevalence (%)	Mean intensity	Site of infection
<i>Ichthyophthirius multifiliis</i>	4	2.66	10	Skin, Fins & Gills
<i>Trichodina reticulata</i> ** α	5	3.33	12	Skin & Fins
<i>Gyrodactylus baikalensis</i> **	5	3.33	4.4	Skin
<i>Gyrodactylus elegans</i>	3	2	5.66	Skin & Fins
<i>Gyrodactylus gobioninum</i> *	2	1.33	3	Skin
<i>Gyrodactylus vicinus</i>	7	4.66	5.28	Skin & Fins
<i>Diplostomum spathaceum</i>	2	1.33	4	Eye lens
<i>Bothriocephalus acheilognathi</i>	3	2	5	Intestine
<i>Lernaea cyprinacea</i>	4	2.66	3	Skin & Gills

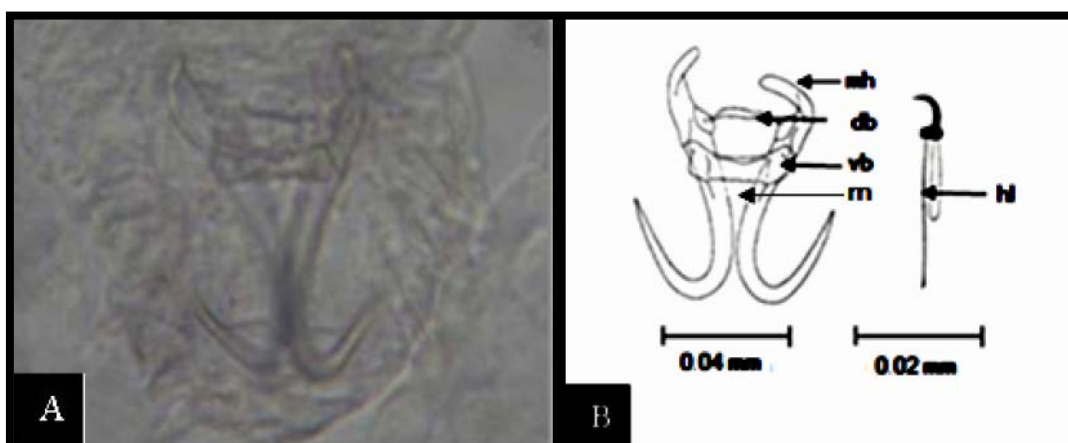* First record in Iraq.

** First record in Kurdistan region.

 α New host record in Iraq.**Fig. (1): *Trichodina reticulata*.**

A- Photomicrograph (500X); B- Camera lucida drawing.

ad= adhesive disc; b= blade; cad= central of adhesive disc; ci= cilia; r= ray.

**Fig (2): *Gyrodactylus baikalensis*.**

A- Photomicrograph of the haptor (500X); B- Camera lucida of the haptor.

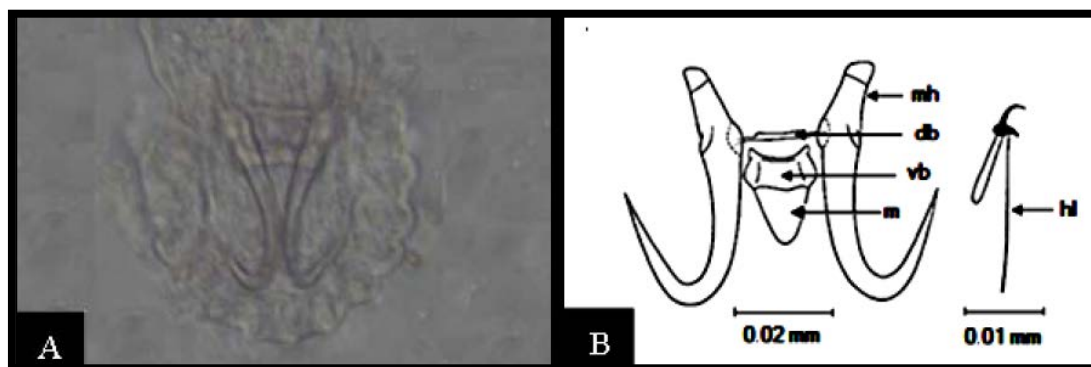


Fig. (3): *Gyrodactylus gobioninum*.

A- Photomicrograph of the haptor (500X); **B-** Camera lucida of the haptor.
db= dorsal bar; **hl**= hooklet; **m**= membrane; **mh**= median hook; **vb**= ventral bar.