

ANGIOGRAPHIC STUDY OF THE NORMAL CORONARY ARTERY IN PATIENTS ATTENDING ULAIMANI CENTER FOR HEART DISEASES

Dr.Imad Ghanem Shukri, M.B.Ch.B, M.Sc., FICMS

Assistant Professor in Clinical and applied anatomy, University of Al-Mustansaria, College of medicine, Department of anatomy, Baghdad-Iraq

***Dr. Jawad Mohammed Hawas, M.B.Ch.B, CABM, FICMS
Medicine, FICMS Cardiology, Consultant cardiologist***

University of Sulaimani, College of medicine,
Department of Medicine, Sulaimania-Iraq

***Dr. Shilan Huseein Karim, M.B.Ch.B, MSc, PhD Human
anatomy, Lecturer***

Dr. Issraa Khalil M. Ali, B.D.S, MSc Human anatomy

University of Sulaimani, College of Medicine,
Department of Anatomy, Sulaimania-Iraq

Abstract

Background and aim: There is no available data on normal coronary artery dimensions among Iraqi Kurdish population (Sulaimani region), so that our aim is to study the normal dimensions of the coronary artery segments during life by using quantitative coronary angiography with reference to dominancy and variations and possibly to help interventional cardiologist and cardiac surgeon.

Methods: Between February 2009 to June 2009, 88 patients underwent quantitative coronary angiography for evaluation of symptoms of ischemic heart disease and were found to have no coronary artery disease from the sample size.

Results: The diameter of the coronary arteries were larger in male subjects than females with significant p-value for LMCA, proximal LAD, LCx and RCA regarding proximal RCA also was larger among male but statistically was non significant. The diameter of the coronary arteries in Kurdish population were similar to Caucasians and white but greater than that of Indians.

Conclusion:In general males has larger coronary artery diameter than females, the mean diameter was similar to that reported in Caucasians and white and larger than Indians.

Keywords: Coronary angiography, coronary artery, coronary variation

Introduction:

Coronary artery disease is one of the major causes of death in developing countries. More progress has been made in the last few decades than in all foregoing medical history in the management of cardiovascular diseases (Huma et al, 2006).

Today, with the widespread use of new imaging diagnostic techniques and the development of non-aggressive treatments, a thorough knowledge of the normal coronary anatomy and its variations and/or anomalies is essential (Mcconnell et al, 1995, Post et al, 1995, Ropers et al, 2001) .

Accurate description of the extent of coronary atherosclerosis is predicated by understanding the normal coronary anatomy; however studies concerning luminal dimensions of truly normal coronary arteries are limited. Several studies have evaluated the dimensions of postmortem coronary arteries (Ehrlich et al, 1931, Rodriguez and Robbin, 1959, Wilens et al, 1966, Hutchins et al, 1977).

There have been very few studies of normal (undiseased) coronary artery size performed during life using quantitative coronary arteriographic (QCA) techniques in living patients with presumably normal arteries (MacAlpin et al, 1973, Vieweg et al, 1976, Ratib and Mankovich, 1988, Hermiller et al, 1992, Dhawan and Bray, 1995).

Knowledge of the normal and variant anatomy and anomalies of coronary circulation is an increasingly vital component in the management of congenital and acquired heart diseases (Kalpana, 2003).

Traditional way of expressing severity of coronary artery stenosis is by percentage stenosis, prediction of normal coronary dimensions may overcome the inadequacies of percentage stenosis in diffuse coronary artery diseases .To define the presence of such diffuse disease angiographically, the size of the disease-free artery at such site in the coronary tree must be known (Brown et al, 1977, Harrison et al, 1984, Fleagle et al, 1989, Johnson et al, 1988, Vicram et al, 2005).

Measurement of absolute coronary dimensions, defined by the use of artery lumina are obtained by using catheter, these techniques are validated and widely accepted method to investigate changes in arterial dimensions over time (Harrison et al, 1984, Fleagle et al, 1989, Hermiller et al, 1992, Herrman et al, 1994, Tadehara et al, 2001) .

Previous postmortem and angiographic studies have evaluated the relation between cardiac anatomical features and coronary arterial size, it has been found that coronary arterial size varies directly with ventricular wall mass (Lewis and Gotsman, 1973, MacAlpin et al, 1973, Leung et al, 1991, Paulsen et al, 1975, Hutchins et al, 1977, Roberts and Roberts 1980, O’Keefe et al, 1987).

There is also postmortem observation and animal studies suggesting that the amount of myocardium supplied by a coronary vessel is related to the size of that proximal vessel (Rodriguez and Robbin, 1959, Koiwa et al, 1986).

In the field of cardiology, coronary arteries do not usually show up on x-ray only if calcified, but coronary angiography allows them to be seen by injecting a special dye that shows up on x-ray. Angiography remain the gold standard for diagnosis of coronary artery diseases, it provides both anatomical and physiological information about coronary flow (Ito et al, 1992, Bittl and Levin, 1997, Vanthof et al, 1998, Tarantini et al, 2006, Bugiardini et al, 2007).

Coronary circulation:

The heart works continuously, and cardiac muscle cells require reliable supplies of oxygen and nutrients. The coronary circulation supplies blood to the muscle tissue of the heart. During maximum exertion, the oxygen demand raises considerably, and the blood flow to the heart may increase to nine times above resting levels. The coronary circulation includes an extensive network of coronary blood vessels (Frederic et al, 2003).

The heart is supplied by the two coronary arteries and their branches. The right and left coronary arteries (RCA and LCA) originate at the base of the ascending aorta, within the aortic sinus, as the first branches of this vessel. Blood pressure here is the highest found anywhere in the systemic circuit, and this pressure ensures a continuous flow of blood to meet the demands of active cardiac muscle tissue. Variations occur occasionally in their origin and pattern of distributions. Each coronary artery is the main source of supply to its same side atrium and ventricle, but also supply opposite side chambers to some extent (Frederic et al, 2003, Sinnatamby, 2006).

Coronary artery anastomoses:

Anastomoses between right and left coronary arteries are abundant during fetal life, but are much reduced by the end of the first year of life (Standring et al, 2005).

There are interarterial coronary connections between different branches of the same coronary artery (homocoronary collateral circulation) or between different coronary arteries (heterocoronary collateral circulation) (Cohen, 1985).

Because the arteries are interconnected in this way, the blood supply to the ventricular muscle remains relatively constant, regardless of pressure fluctuations within the left and right coronary arteries (Frederic et al, 2003).

The functional value of such anastomoses is variable, but they appear to become more effective in slowly progressive pathological condition, it may become valuable and most effective in conditions of hypoxia and in chronic coronary artery diseases, but they are usually not large enough to provide an adequate blood supply to the cardiac muscle when one of the large branches is blocked completely by disease. A sudden block of the larger branches of one of the coronary arteries usually lead to myocardial death (myocardial infarction). The most frequent sites of anastomoses are the apex, the anterior aspect of the right ventricle, the posterior aspect of the left ventricle, crux and interarterial and interventricular groove (Snell, 2004, Strandring et al, 2005).

Variations in the coronary arteries:

The arrangement of the coronary arteries varies considerably among individuals. Coronary arteries normally found in pairs, may vary in origin, distribution and size, these arteries emit several branches responsible for irrigating the whole surface and interior heart tissue (Strandring et al, 2005).

Coronary artery dominance:

The concept of right or left dominant was first proposed by Schlesinger in 1940. This term used to refer to the coronary artery that gives the PDA which supplies the diaphragmatic surface of the heart. (Schlesinger, 1940, Strandring et al, 2005)

This term is frequently used but is potentially misleading; it could be taken to mean that the dominant coronary is the one that irrigates the greater part of the myocardium, but in fact it is always the LCA that does so .The term refers to the supply of the heart's diaphragmatic surface of both ventricles, which may be the right or left coronary artery (Reig, 2003).

The artery that supplies the PDA determines the coronary dominance (Fuster et al, 2001)

The dominancy is determined as follow:

1) If the RCA supplies the PDA, the circulation can be classified as **right-dominance**. Fig. (1.5)

2) If the LCx artery, a branch of LMCA, supplies the PDA, the circulation can be classified as **left dominance**. Fig. (1.6)

3) If branches of both arteries (RCA and LMCA) run in or near the posterior interventricular groove, the PDA, the circulation can be classified as *co-dominant*.

Schlesinger, (1940) reported right dominance in 58% of hearts, left dominance in 18% and a balance in 34%.

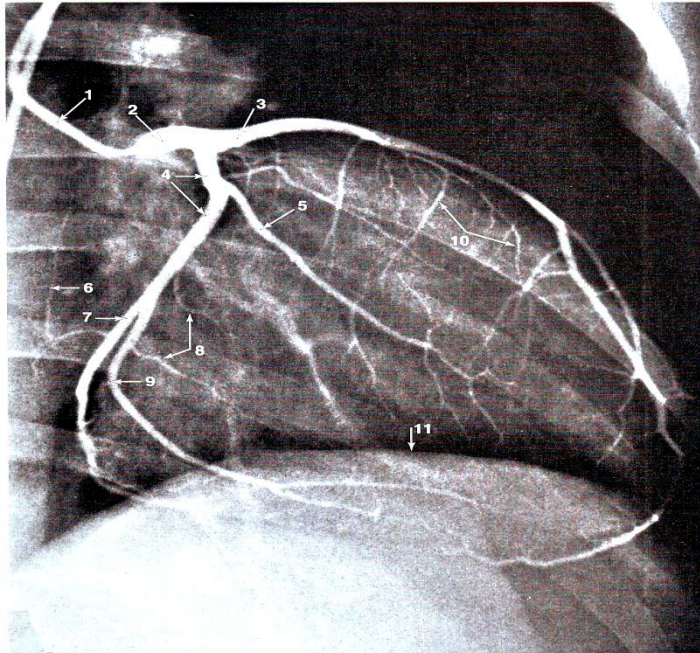
Right dominance is present in most individuals (90%) of general population and left dominance is about (10%) (Sinnatamby, 2006, Carmine, 2007, Snell, 2008).

Coronary Angiography:

It is a minimally invasive procedure to access the coronary circulation and blood filled chambers of the heart using specially designed catheter, it is performed for both diagnostic and interventional (treatment) purposes (Connolly, 2002).

The exact anatomy of the myocardial blood supply system varies considerably from person to person; a full evaluation of the coronary arteries dimensions accurately requires coronary catheterization or CT coronary angiography (Fuster et al, 2001, Skelton et al, 1987).

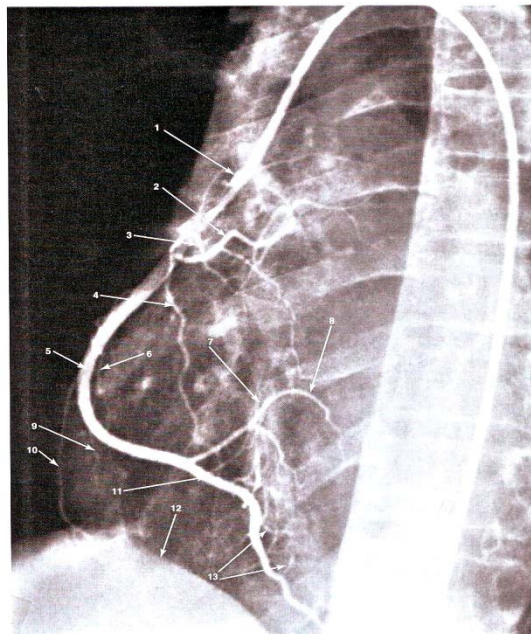
Coronary angiography is one of the several cardiology diagnostic tests and procedures, its a visually interpreted test performed to recognize occlusion, stenosis, restenosis, thrombosis or aneurysmal enlargement of the coronary artery lumens; heart chamber size; heart muscle contraction performance, even with the advent of new non invasive imaging modalities such as Cardiac CT and MRI, coronary angiography remain the gold standard for detecting clinically significant coronary diseases (Connolly, 2002).



Left Coronary Arteriogram

NOTE that this arteriogram of the left coronary artery is viewed from a right anterior oblique direction.

- | | | | |
|-------------------------------------|---------------------------------------|---|---------------------|
| 1. Catheter | 4. Circumflex branch | 7. Left posterolateral branch of circumflex | 10. Septal branches |
| 2. Left coronary artery | 5. Left marginal branch of circumflex | 8. Posterior interventricular branches | 11. Diaphragm |
| 3. Anterior interventricular branch | 6. Posterior atrial branch | 9. Posterior interventricular branch | |



Right Coronary Arteriogram

NOTE that this arteriogram of the right coronary artery is viewed from the left anterior oblique direction.

- | | | |
|--------------------------------|---------------------------------|---------------------------------------|
| 1. Catheter | 5. Right coronary artery | 9. Posterior ventricular branch |
| 2. Sinoatrial node branch | 6. Anterior ventricular branch | 10. Right marginal branch |
| 3. Conus arteriosus branch | 7. Atrioventricular node branch | 11. Posterior interventricular branch |
| 4. Anterior ventricular branch | 8. Posterior ventricular branch | 12. Diaphragm |
| | | 13. Posterior septal branches |

Fig.(2.2)

Patients and Method

Patients:

Between February 2009 and July 2009, 88 patients (29 males and 59 females) their ages range between 27-70 years; underwent coronary angiography for evaluation of symptoms of chest pain and ischemic heart diseases at Sulaimani Center for Heart Diseases, but their angiograms were normal.

Exclusion criteria:

Patients with previous history of ischemic heart disease, Coronary Artery By Pass Graft, Patients with Valvular heart disease, Diabetes Mellitus, Hypertensive patients who have left ventricular hypertrophy and Patients who have sever tortuous vessels.

The baseline clinical status and demographic data were obtained from the hospital records and comprised of patients from Sulaimani City district and the surrounding area were included and studied.

Before the procedure:

All patients were seen by their physician a day before the procedure, full clinical assessment done ,the essential hematological and biochemical test done for them which included the followings: Virology (HBs Ag, HCV Ab, HIV), Hematology (Hb, WBC, platelet count), Biochemical (Blood sugare ,blood urea, serum creatinin), Lipid profile (Serum cholestrol, Serum triglyceride).

Reviewing of the echocardiography report done to exclude valvular heart disease and the presence of left ventricular hypertrophy.

For patients on chronic oral anticoagulation therapy should discontinue 3 days before the procedure with (INR<2.0).

The procedure and its risk are explained in such terms that the patients gives truly informed consent .Then they are instructed to be fasting over night(except oral medications),both groins to be shaved and to come early morning to the catheterization laboratory.

At the procedure day:

New Electrocardiography (ECG) and complete vital signs should be recorded after arrival, intravenous canula is inserted in place, and the patient should empty the urinary bladder before being taken to the catheterization laboratory and their clothes changed with sterile gown .All patients should receive sedation before the procedure to relief the stress of the procedure with out going to sleep.

The patient is able to ask questions and follow our requests, like taking a deep breath, cough or let us know if there is any discomfort, coughing helps clear the contrast from the coronary artery.

The aim behind such treatment is to keep the patient extremely comfortable without being put to sleep. This process is known as conscious sedation (Goodman, 2001).

When preparations have been finished and the catheterization laboratory is ready, the patient will be transferred.

The catheterization laboratory consists of a patient support table, radiographic device (GE Innova 3100) model 2004, with digital cinefilmless archiving and a floor mounted system that allow variable angulations of the x-ray beam through the patients. Fig. (2.1)

The x-ray system is a flat panel detector design. The room also has equipment for monitoring intracardiac pressures, ECG activity and all necessary emergency resuscitation tools including defibrillator and ventilator. The control and recording equipment situated in a separate room that has a window made of lead-treated glass and provides excellent verbal communication and rapid access to the procedure room. The generator and its associated electronics are placed in ventilated room beside control room. In the catheterization laboratory there will be a primary operator (physician) who will perform the procedure with 3 other staff: (a nurse for assistance, one for haemodynamic measures and a radiological technologist) they will all wear sterile gown, gloves and mask, the staff are wearing lead apron and thyroid collar for protection from radiation. While the patient is on the table his both groin are sterilized with povidon iodine for the chance that the other groin may have to be used and is covered with sterile blue or green sheets covering the whole patient up to the head, the covering towel has two holes in groin area.

Catheterization is most commonly performed from right femoral artery which is located in the right groin. Occasionally the right or left arm (brachial artery) or wrist (radial artery) approach may be employed.

Fig (2.2)

The x-ray system is a flat panel detector design. The room also has equipment for monitoring intracardiac pressures, ECG activity and all necessary emergency resuscitation tools including defibrillator and ventilator. The control and recording equipment situated in a separate room that has a window made of lead-treated glass and provides excellent verbal communication and rapid access to the procedure room. The generator and its associated electronics are placed in ventilated room beside control room. In the catheterization laboratory there will be a primary operator (physician) who will perform the procedure with 3 other staff: (a nurse for assistance, one for haemodynamic measures and a radiological technologist) they will

all wear sterile gown, gloves and mask, the staff are wearing lead apron and thyroid collar for protection from radiation .While the patient is on the table his both groin are sterilized with povidon iodine for the chance that the other groin may have to be used and is covered with sterile blue or green sheets covering the whole patient up to the head, the covering towel has two holes in groin area .

Catheterization is most commonly performed from right femoral artery which is located in the right groin. Occasionally the right or left arm (brachial artery) or wrist (radial artery) approach may be employed.

Fig (2.2)

Local anesthesia induced by injecting lidocaine into the skin and adjoining area of the groin.

The femoral arterial access is the most common access for performing coronary angiography. Anatomical landmarks are used to identify the correct site of arterial puncture; the femoral head provide the best visible landmark with arterial puncture below the inguinal ligament. The front wall of the artery is punctured by using 18G Cook needle on the maximal feeling of pulsation as palpated by the fingers .When vigorous pulsatile

flow seen it means arterial blood, then the J tip guide wire will be advanced into the needle, by Seldinger technique (Seldinger, 1953).

Fig. (2.3).

Once the guide wire is at the level of the diaphragm, the needle will be removed, appropriate sized vascular sheath will be advanced with a rotational motion (in all cases of this study a 6F sheath is used) that is equipped with a one-way valve that allows catheters to be introduced through the sheath but prevents blood from artery to come out through the sheath and side arm tubing. Then the desired catheter (usually beginning with JL) flushed and loaded with a J guide wire and it is introduced into the sheath, an arterial (6French) sheath is inserted in to the femoral artery and selective coronary catheterization is carried out with 6th french Judkins or Amplatz right and left coronary catheters as in fig. (2.4).

Selective hooking of the coronary ostium is performed and 7-8ml non ionic contrast (Iohexol 350mg /ml) is administrated by hand injection. Images were then acquired for each coronary artery segment in two or more orthogonal views and the mean of the two values was taken for statistical analysis. Then the soft end of the guide wire will be advanced carefully through the catheter, to the level of the diaphragm before the catheter itself advanced.

The catheter is then rotated and gently manipulated to guide its tip to the opening of the coronary artery. Once the coronary vessels have been engaged, selective angiography requires transient but nearly complete

replacement of blood flow by injecting radiopaque contrast material into the opening of a coronary artery allow the coronary arteries to be visualized.

Usually a diagnostic coronary angiography without complications will take 10-15 minutes. All angiograms were reviewed by two interventional cardiologist (Dr. Jawad and Dr. Mahir) both for definition of normal vessels and subsequent quantitative analysis.

The decision that this angiogram is normal coronary artery is done for all cases also by the same two cardiologist (Dr. Jawad and Dr. Mahir).

The following parameters were observed:

1- Diameters of proximal LMCA, proximal LAD, proximal LCx and proximal RCA.

2- The percentage of right, left and co dominant circulation.

3- Types of LAD artery.

Type 1: the LAD artery do not reach to the apex of the heart.

Type 2: the LAD artery reach to the apex of the heart.

Type 3: the LAD artery reach beyond the apex of the heart.

4- Length of LMCA :

1- Short (equal or less than 5 mm).

2- Normal range (between 5-15 mm).

3- Long (more than 10mm).

It is important to know that the proximal portion of the artery is defined as the part of the vessel before the origination of any branches (Amgad et al, 2005).

QCA measurement :

Calibration of the Quantitative Coronary Angiography (QCA) system was carried out by method in which the coronary catheter employed for angiography itself was used as the calibration object by automated edge detection technique resulting in corresponding calibration factors (mm/pixel) and the vessel contour was detected by operator independent edge detection algorithms.

The dimension of the coronary artery was then measured as a function of catheter diameter; the absolute diameter in mm was calculated by the computerized software analysis as in fig (2.5), (2.6) and (2.7).

In general, to avoid vessel overlap, the cranial left anterior oblique view was chosen for proximal LAD, caudal right anterior oblique view for LMCA and proximal LCx, and left anterior oblique view for proximal RCA .These measurement were made at end diastolic cine-frames.

Angiographic views were selected to minimize foreshortening of the involved coronary segment and to separate them from adjacent intervening structure.

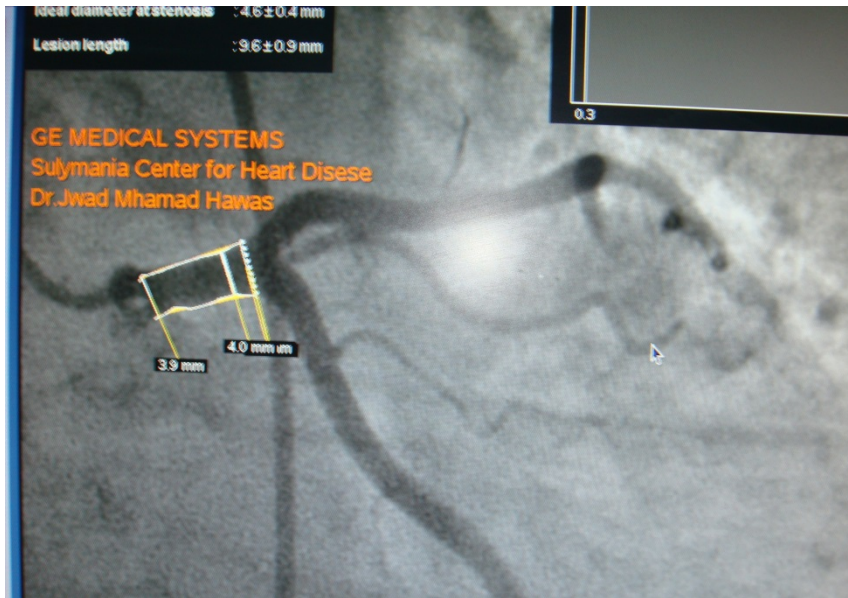


Fig. (2.5) QCA measurement of LMCA

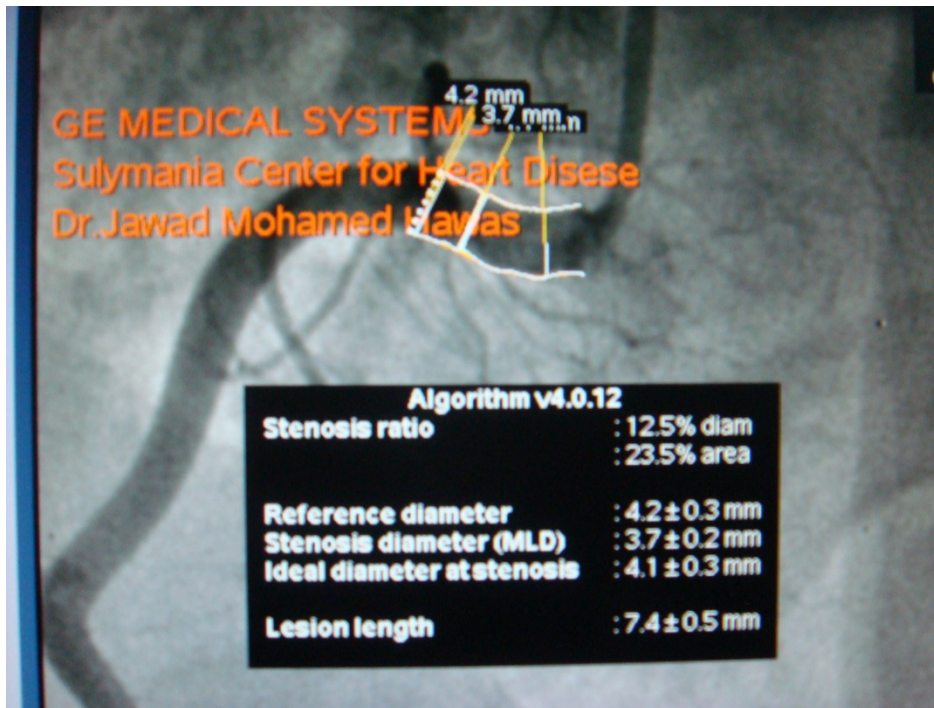


Fig. (2.6) QCA measurement of RCA

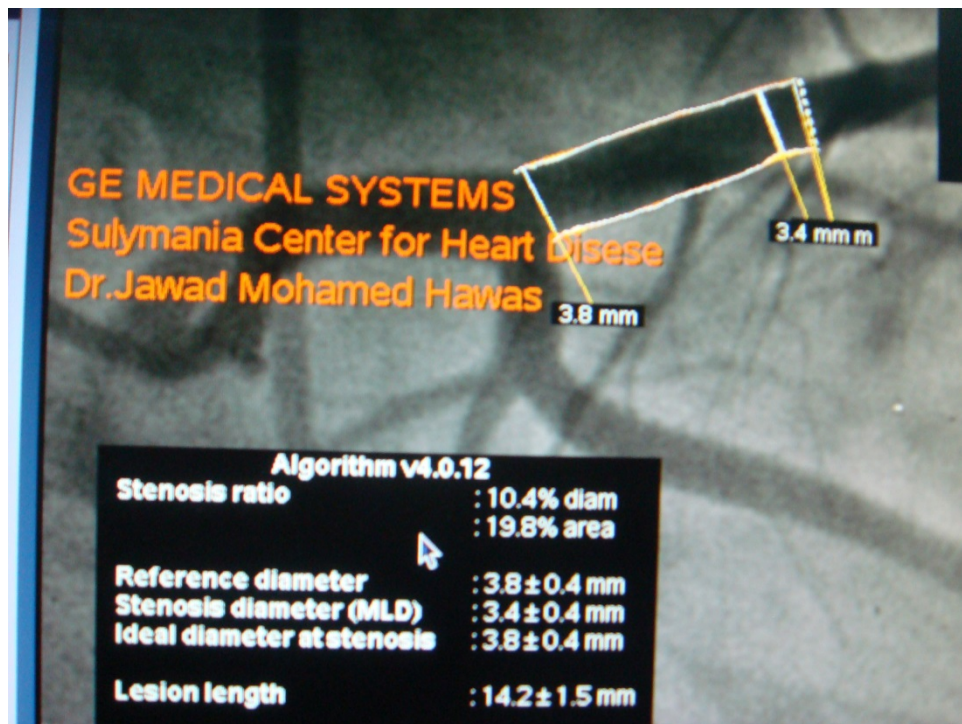


Fig.(2.7) QCA measurement of LAD

Statistical analysis:

The data were translated into codes using a specially designed coding sheet, and then converted to computerized database.

Statistical analysis was performed using the SPSS software package for Windows version 15.0.

Student t-test was used for comparison of differences in coronary artery dimensions among males and females, while correlations between diameter of coronary arteries and age were estimated by pearson correlation coefficient.

Correlation between LMCA diameter and diameters of LAD and LCx arteries also estimated by pearson correlation coefficient.

Method of evaluation of the correlation is as follow:

If the value is equal to zero, means there is no correlation.

If the value is between zero and 0.5, means weak positive correlation.

If the value is between 0.5-1, means strong positive correlation.

If the value is between zero and -0.5, means weak negative correlation.

If the value is between -0.5 and -1, means strong negative correlation.

P-value (less than 0.05 was considered statistically significant).

Results:

Of the 88 patients, 59(67%) were females and 29 (33%) were males with mean age \pm standard deviation of 52.1 ± 9.6 .

The major complaint of patients was chest pain in (90 %) and dyspnea in (10 %) of them, 36.4% were hypertensive and 63.6% were normotensive. Regarding coronary dominance 65% was right dominant circulation, 27% mixed circulation and 8% were left dominant circulation .Table (3.1)

Table (3.1) Demographic charadteristic of samples

<i>Demographic data</i>	
Number	88
Sex (M: F)	29:59
Age	Range 27-70 years
<i>Clinical characteristics</i>	
Chest pain	90%
Dyspnea	10%
Hypertension (Yes: No)	32: 56
<i>Coronary dominance</i>	
Right	65%
Left	8%
Co-dominant	27%

Diameters of LMCA, LAD, LCx and RCA:

In general the mean diameters of LMCA was (4.63 mm), LAD (3.42 mm), LCx (3.12 mm) and RCA (3.11 mm). Table (3.2)

Table (3.2) Mean diameter of LMCA, LAD, LCx and RCA in general

Artery name	LMCA	LAD	LCx	RCA
Patients number	84	88	88	88
Diameter (mm)	4.63	3.42	3.12	3.11

In general males had larger coronary artery diameter as compared to females.

The mean diameter in males (in mm) for LMCA (4.86 ± 0.77), proximal LAD (3.60 ± 0.58), proximal LCx (3.26 ± 0.62) and proximal RCA (3.26 ± 0.65), while the mean diameter in females (in mm) for LMCA (4.50 ± 0.73), proximal LAD (3.31 ± 0.46), proximal LCx (3.03 ± 0.39) and for proximal RCA (3.02 ± 0.55). Table (3.3)

The males had a statistically significant larger coronary artery diameter for the LMCA, proximal LAD and proximal LCx ($p < 0.05$). The difference between males and females however was not significant in the proximal RCA.

Table (3.3) Comparison of coronary artery diameter among males and females.

The Artery	Male			Female			T- test	P- Value
	Number	Mean diameter	Std. Deviation	Number	Mean diameter	Std. Deviation		
LMCA (mm)	30	4.86	0.77	54	4.50	0.73	2.09	0.03
LAD (mm)	32	3.60	0.58	56	3.31	0.46	2.49	0.01
Lcx (mm)	32	3.26	0.62	56	3.03	0.39	2.11	0.03
RCA (mm)	32	3.26	0.65	56	3.02	0.55	1.85	0.06

P-Value <0.05 regarded as significant

Correlation between coronary artery diameter with age:

There was a weak positive correlation between the patients age and the diameters of LMCA, proximal LAD, proximal LCx and proximal RCA which was statistically non significant as shown in table (3.4) and represent graphically in fig (3.1), (3.2), (3.3) and (3.4).

Table (3.4) Correlation between age of the patients and coronary artery diameter.

		LMCA mm	LAD mm	Lcx mm	RCA mm
Age	Pearson Correlation	0.08	0.13	0.11	-0.003
	Sig. (2-tailed)	0.44	0.21	0.28	0.976
	Number	84	88	88	88

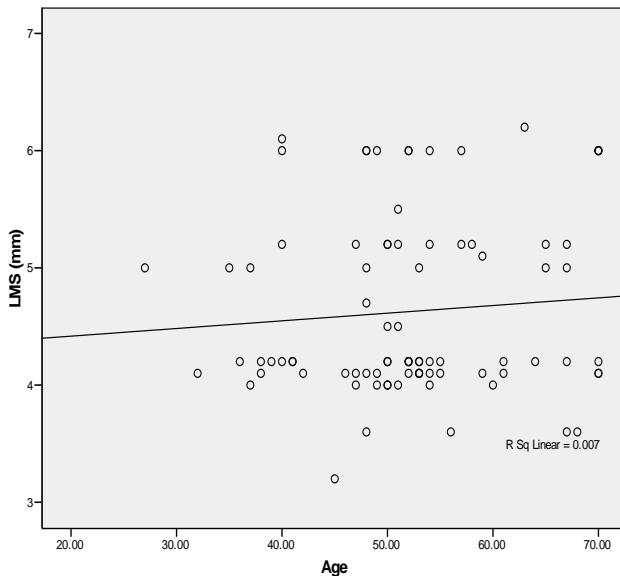


Fig. (3.1) Simple scatter chart showing correlation between LMCA and age

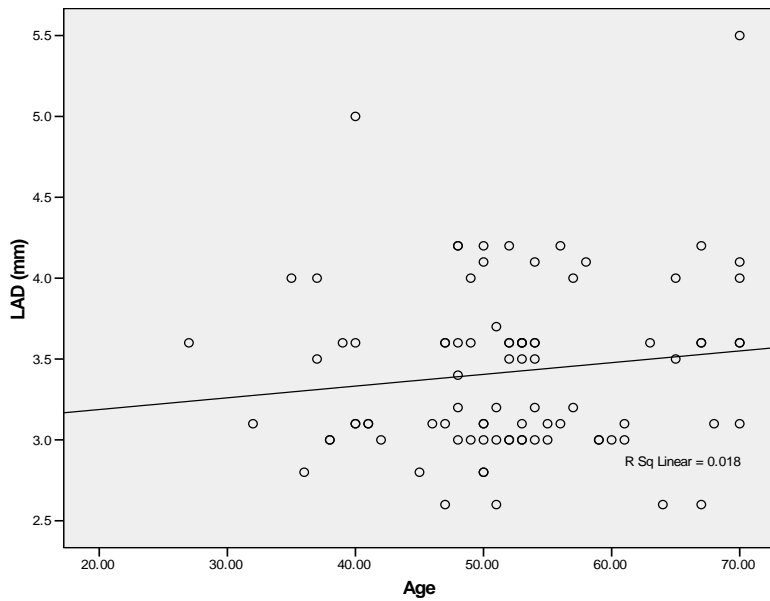


Fig (3.2) Simple scatter chart showing correlation between LAD artery and age

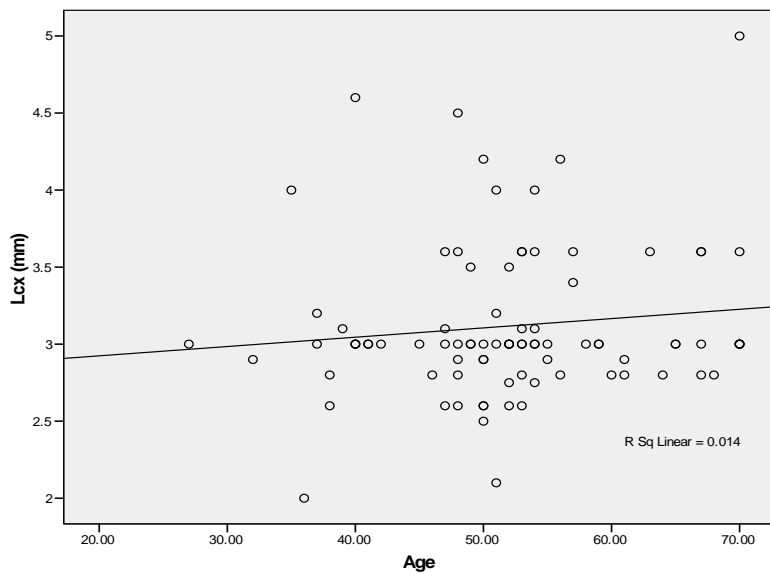


Fig (3.3) Simple scatter chart showing correlation between LCx artery and age

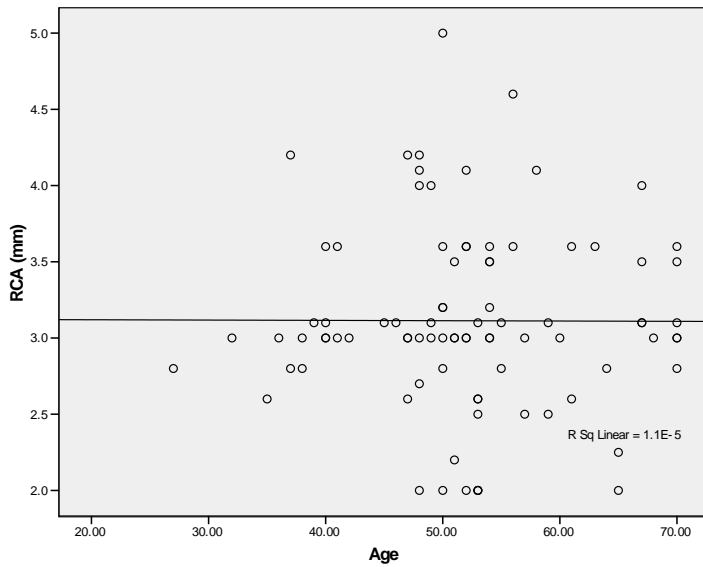


Fig (3.4) Simple scatter chart showing correlation between RCA and age.

Coronary artery dominancy:

The present results describe a higher percentage of right coronary dominance in all cases studied regardless of gender. In general the type of dominancy was right sided in 64.8%, co-dominant in 27.3% and left dominant in 8%. Table (3.5).

Type of dominancy	frequency	Percentage
Right	57	64.8
Left	7	8.0
Co dominant	24	27.3
Total	88	100.0

Fig (3.5) shows the details of dominancy in both sexes.

The percentage of right dominant circulation was 53.1 % in males and 71.4 % in females.

For co dominant circulation was 37.5 % for males and 21.4 % for females, while the percentage of left dominant circulation was 9.3% for males and 7.1% for females.

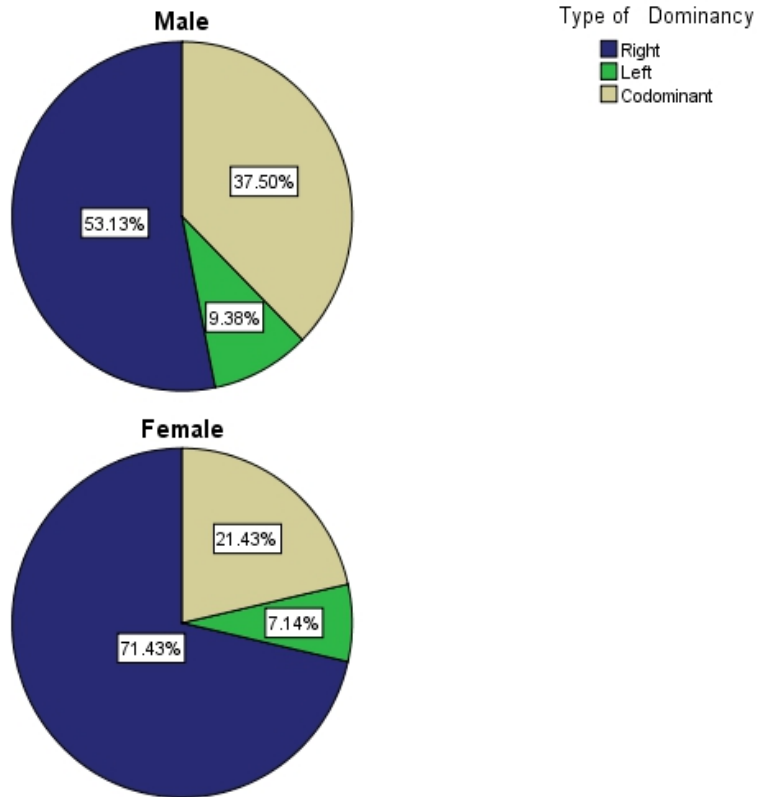


Fig (3.5) Pie chart showing types of coronary dominancy in both sexes

5 Length of the LMCA:

For the length of LMCA we report 4 cases (4.5%) of separate ostia for LAD and LCx arteries (mean the length is equal to zero).

For the remainder 38.6 % was short (less than 5 mm), in 43.2 % of cases the length of LMCA was within normal range (between 5-15 mm), and 13.6 % was long (more than 15 mm). Table (3.6), Fig (3.6)

Table (3.6) Length of LMCA

LMCA length	Frequency	Percent
Short	34	38.6
Normal length	38	43.2
Long	12	13.6
Total	84	95.5
Separate ostia	4	4.5
Total	88	100.0

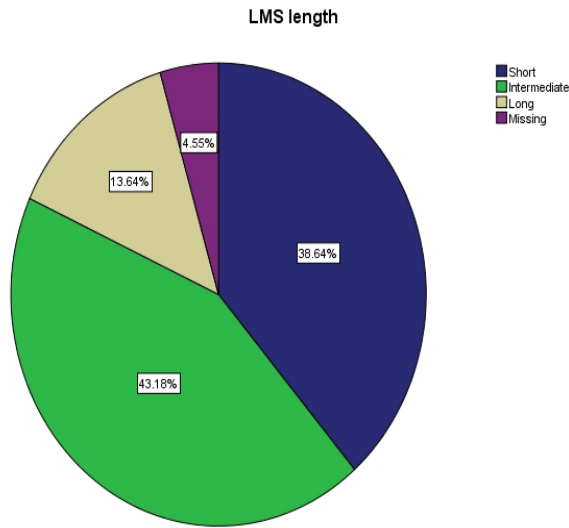


Fig (3.6) Pie chart showing the length of LMCA

Types of LAD artery:

Table (3.7) and fig (3.7) show the results of LAD length with a value of 45.5 % for type 3 (reach beyond the apex of the heart), 44.3 % for type 2 (reach the apex) and 10.2 % for type 1 (terminate before reaching the apex).

Table (3.7) Types of LAD artery

Types of LAD	Frequency	Percent
Type 1	9	10.2
Type 2	39	44.3
Type 3	40	45.5
Total	88	100.0

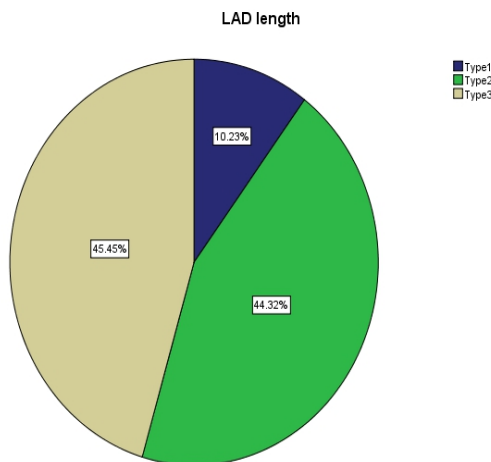


Fig (3.7) Pie chart showing the types of LAD artery

Correlation between length of LAD artery and right coronary dominance:

There was an inverse relationship between the length of LAD and right dominant circulation with 100% right sided dominance in those with type 1 LAD, 74% right sided dominance for those with type 2 LAD and 47% of those with type 3 LAD have right dominance. Table (3.8)

Table (3.8) Correlation between LAD types and right coronary dominance

Type of LAD	Right Dominancy	
	Frequency	Percentage
Type 1	9	100%
Type 2	29	74%
Type 3	19	47%

Correlation between LMCA diameter and diameters of LAD and LCx arteries:

There was a strong positive correlation between the diameter of the LMCA with the diameter of proximal LAD artery and a weak positive correlation between the diameter of LMCA with the diameter of LCx artery, but both of them was statistically significant as showing in table (3.9), fig. (3.8) and (3.9).

Table (3.9) Correlation between LMCA diameter and diameters of LAD and LCx arteries

LMCA versus	Pearson's Correlation Coefficient
LAD (mm)	.623(**)
LCx (mm)	.428(**)

All these value are statistically significant**

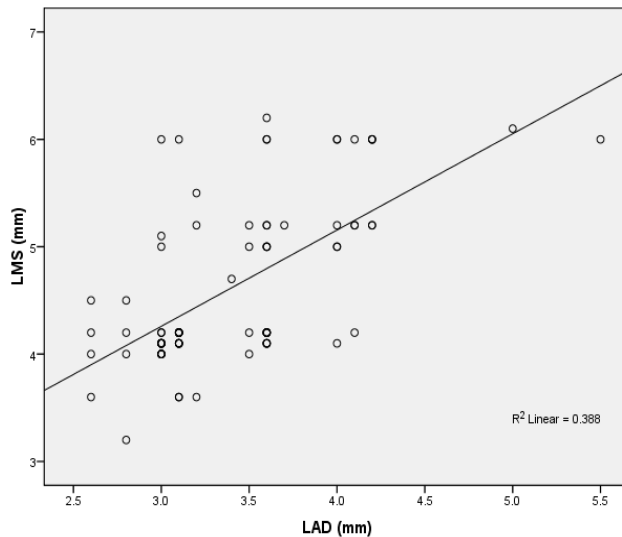


Fig. (3.8) Simple scatter chart showing correlation between LMCA and LAD artery

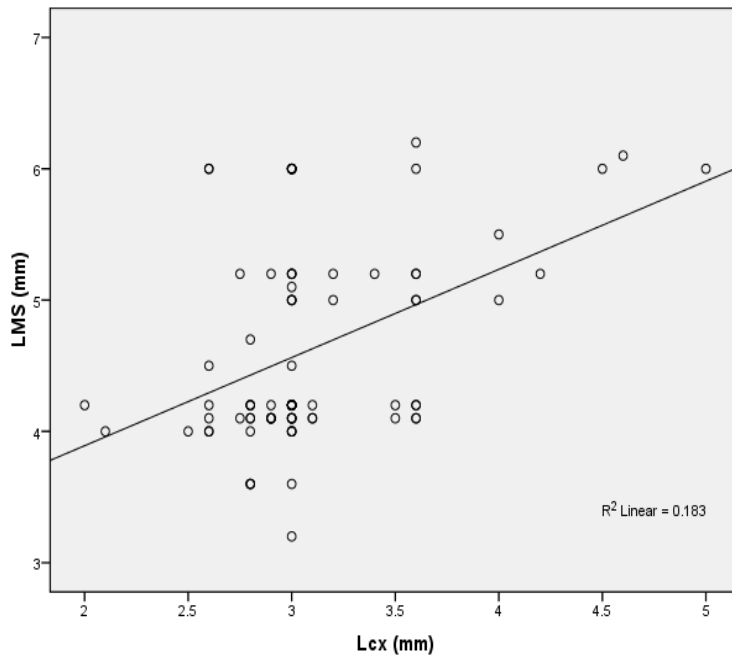


Fig. Simple scatter chart showing correlation between LMCA and LCx artery

DISCUSSION:

The dimensions of the coronary arteries are highly variable in the normal population (Lewis et al, 1970, Restrepo et al, 1973, Hermiller et al, 1992).

Previous studies of normal human coronary artery dimensions have been performed primarily in postmortem hearts (Ehrlich et al, 1931, Rodriguez and Robbins 1959, Wilens et al, 1966, Hutching et al, 1977)

Most of these studies obtained coronary measurements under physiologically distending pressures, postmortem alterations in smooth muscle distensibility that might affect actual coronary caliber. Therefore, necropsy examination may not accurately reflect angiographic coronary dimensions measured during life (Leung et al, 1991).

Coronary angiography remains the standard of measuring coronary artery diameter; it is the principle for defining the anatomy of arteries in living beings (Ross, 1987).

Since there is no previous study or database in our locality about normal dimensions of the arteries of the coronary circulation in normal living subjects, we use quantitative coronary angiography to measure the dimensions of the coronary arteries for those subjects who has stenosis free coronary angiographs.

4.1 Diameters of LMCA, proximal LAD, LCx and RCA in relation to gender:

Quantitative coronary angiogram (QCA) aims to gain a geometric as well as functional evaluation of coronary artery dimensions. Geometric measurement allows the immediate assessment of coronary artery diameter (MacAlpin et al, 1973).

Several studies have validated the accuracy of digital QCA for estimation of coronary dimensions (Vogel, 1985, Rensing et al, 1992, Dhawan and Bray 1994).

In the present study we measured the diameters of the above mentioned arteries because these arteries are the most important and most commonly arteries that involved in atherosclerotic process.

The mean diameters of LMCA, proximal LAD, proximal LCx and proximal RCA as shown in table (3.2), were similar to the results of studies done by Kaimkhani (2004) in Pakistan: LMCA (4.28 mm), LAD (3.22 mm), LCx (3.02 mm) and RCA (3.08 mm), Vikram et al, (2005): LMCA (4.3 mm), LAD (3.48 mm), LCx (3.16 mm) and RCA (3.15 mm) and Amgad et al, (2005): LMCA (4.0 mm), LAD (3.1 mm), LCx (3.0 mm) and RCA (3.1 mm), in which they measure the diameters of the coronary arteries by QCA.

There was partial correlation between the present study and a study done by Leung et al, (1991) in USA in which the diameters of LMCA was (4.4 mm), while the diameters of proximal LAD (2.9 mm), LCx (2.8 mm) and RCA was (2.8 mm), these measurement are smaller than the results of the present study and this is probably due to the fact that the American population is of mixed races.

The mean diameter of the above mentioned arteries in the present study was significantly larger than the mean diameters obtained by Cheemalapati et al, (2006) in India, in which the diameters of LMCA was (3.55 mm), LAD (2.8 mm), LCx (2.75 mm) and RCA was (2.65 mm) this is probably due to small body build of Indian populations, as it was found by Vikram et al, (2005) that coronary artery dimension correlated with body weight.

Also our results shows gender differences with larger diameters of the above mentioned arteries in males compared to the females which was statistically significant for LMCA, proximal LAD, proximal LCx, and not for proximal RCA, this was compatible with the results of the studies done by Dhawan and Bray, (1995), Lip et al, (1999) and Cheemalapati et al, (2006) in which they measure the coronary artery dimensions by angiography.

In addition, it was similar to the results obtained by Nils et al, (2001) in Switzerland in which they measured the coronary artery diameter by Trans Esophageal Echocardiography (TEE) and with the results of the study done

by Kim et al, (2004) in USA in which they measured the diameter of the coronary artery by Intra Vascular Ultra Sound (IVUS).

There was a partial similarity between our results and the results of the study done by Cheemalapati et al, (2006) in which there was significant difference between males and females regarding the LMCA and non significant difference in regard to remainder arteries.

The reason for these differences is unclear and could be due to racial and genetic factors, differences in body habitus, environmental factors and life style.

Table (4.1) comparison between the present study and other study

Artery name	Caucasian study (2005)	Indian study (2006)	Present study (2009)
LMCA	4.2	3.55	4.63
LAD	3.4	2.8	3.42
LCx	3.3	2.75	3.12
RCA	3.1	2.65	3.11

4.2 Correlation between LMCA diameter and diameters of LAD and LCx arteries:

In our results there was a strong positive correlation between the diameter of LMCA with the diameters of both proximal LAD and LCx as shown in table (3.9) using pearsons correlation coefficient and represent graphically in fig (3.8) and (3.9), this is in agreement with the Indian study by Cheemalapati et al, (2006).

4.3 Correlation between coronary artery diameter with age:

There was a very weak positive correlation between the age of the patients and diameters of LMCA, LAD, LCx and RCA, but the correlation was statistically non significant as shown in table (3.4) and represent graphically in fig (3.1), (3.2), (3.3) and (3.4).

Our result was compatible with the result of the study done by Ehrlich et al, (1931) and Neufeld et al, (1962) which showed slight tendency for adult coronary size to increase with age in postmortem studies.

In contrast there is no change in coronary artery size with aging in three other previous studies conducted by, Rodriguez and Robbin (1959), Wilens et al, (1966) and Hutchins et al, (1977).

4.4 Length of LMCA:

The length of the LMCA normally ranges from 0-15 mm (Hermiller et al, 1993, Douglas et al, 2005).

In the present study we found that 4 cases (4.5%) having separate ostia for LAD and LCx. In a study done by Cavalcanti et al, (1995) the percentage of separate ostia for LAD and LCx was 1.8% , while Saidi et al,

(2002) in Kenya show 2% for separate ostia, both of them was a postmortem studies, this differences probably related to racial differences.

While in a study done by Topaz et al, (1991) in USA the incidence of separate ostia for LAD and LCx was 0.4%, this discrepancy between our result and the result of this study probably related to the larger number of cases involved in later study and ethnic factor may play an important role.

In the present study 43% of the cases, the length of LMCA was between 5-15 mm (normal range), 38% of the cases of the LMCA length was less than 5 mm (short) and 13.6% were long (more than 15 mm) as show in table (3.6), these results was compatible with the results of a study conducted by Charles et al; (1973) (by using angiography), in which the incidence of normal length of LMCA (5-15) was high and the incidence of long LMCA was low.

Also in a study done by Reig and Petit, (2004) their results showed that the most common type of LMCA length was the average one (normal) which is in agreement with our results.

4.5 Coronary artery dominancy:

Anatomical variation of coronary dominance is defined by the presence of a coronary branch irrigating diaphragmatic surface of the heart, which could be originated from either right or left coronary artery. In the present study, right coronary artery branch was found to be responsible for the irrigation of the diaphragmatic surface.

The percentage of dominancy was shown in table (3.5) and represented graphically in fig (3.5), which reveals that the origin of PDA from RCA is the commonest anatomical type in males and females and these values appear to be highly compatible with the results of the following studies in which the percentage of the right sided dominancy was as follow:

Murphy et al, (1977) (63 %), Hutchins et al, (1978) (70 %), Jose et al, (2003) (62.5 %), Kaimkhani et al, (2005) (60 %) and Eren et al, (2008) (70 %). Notably all these above mentioned studies done on patients with normal coronary arteries.

Our results in contrast with the results of the studies done by Kalpana, (2003), Vasheghani et al, (2008) and Frank et al, (2008) in which the percentage of the right dominant circulation was more than in our study and as follow: (89 % versus 65 %), (84 % versus 65%) and (90 % versus 65 %) respectively, this is probably related to racial and ethnic factors and larger sample size involved in all of these studies.

The incidence of the left sided dominancy in the present study was 8 % which is compatible with studies done by Murphy et al, (1973) which was 9 %, Hutchins et al, (1978) was 10 % and Vasheghani et al, (2008) 10 %, all these studies done by angiogram.

Other studies show higher percentage of left sided dominance with value of 11 % by both Cavaleanti et al, (1995) and Kalpana, (2003), 12 % by both Jose et al, (2003) and Eren et al, (2008), and Kaimkhani et al, (2005) with value of 15% .

These differences related to the larger sample size and all of these studies involved cases with normal and diseased coronary arteries in addition to that all of these studies proved that both the coronary artery diseases and variations are more common in individuals with left dominance circulation.

The incidence of co-dominant circulation in present study was 27 % which is similar to the result of study done by Jose et al, (2003) in which the value was 25 % and Kaimkhani et al, (2005) with value of 24 %.

Other studies shows lower incidence of co dominant circulation with value of 20 % for both Hutchins et al, (1978) and Cavalcanti et al, (1995), this discrepancy possibly related to racial factors.

4.6 Correlation between types of LAD artery and right coronary dominance:

In this study we found that 45.5% of the patients having long LAD (type 3), 44.3% type 2 LAD and 10.2 % type 1 LAD (short), as shown in table (3.7) and fig. (3.7).

The results were in agreement with the results of the study done by James, (1961), Perimutt, (1983) and Kalpana, (2003) in which the apex of the left ventricle was supplied by LAD (type 3 LAD) in the majority of cases and supplied by the PDA branch of RCA (type 1 LAD) in minority of cases. Also our results showed that those subjects who has short LAD (type 1) compensated by right dominant circulation, while those with long LAD (type 3) usually have left dominant circulation.

These findings were compatible with the result of the study done by Ilija et al, (2001) who found that those who had short LAD (type 1) were having right dominance and those who had long LAD (type 3) were having left dominance. This means that coronary intervention on patients with type 3 LAD are more risky, because the cardiac apex in such patients are entirely dependent on LAD.

References:

- Alexander R.W. and Griffith G.C., (1956). Anomalies of the coronary arteries and their clinical significance. *Circulation* ; 14, p: 800-805.
- Amgad N. , Makaryus, Bhupesh D. , Jagdeep R. , Avtar R. , Samir G.I., Subir S. , Labana et al, (2005). Coronary artery diameter as a risk factor for acute coronary syndromes in Asian- Indian. *American. J. of Cardiology* ; volume 96, Issue 6, p: 778-780.

- Angelini P. , Villason, Chan A.V. , Diez J.G. , (1999). Normal and anomalous coronary arteries in humans. In: Angelini, P(ed).Coronary artery anomalies. A comprehensive approach. Philadelphia, Lippincot Williams and Wilkins; p: 27-79.
- Ballesteros L.E. and Ramirez L.M. , (2008). Morphological expression of the left coronary artery: a direct anatomical study. *Folia. Morphol. Warsz* ; 67(2), p: 135-142.
- Baptista C.A. , DiDio L.J. , Prates J.C. , (1991). Types of division of the left coronary artery and the ramus diagonals of the human heart. *Jap. Heart. J* ; 32, p: 323-335.
- Baroldi G. and Scomazzoni G. , (1965). Coronary circulation in the normal and pathologic heart. Armed Forces Institute of Pathology, Washington.D.C; p: 1-37.
- Berdajs D. , Kunzli A. , Shurr U. , Zund G. , Turina M.I. , Genonni M. , (2006). Clinical anatomy of the atrioventricular nod artery. *J. Heart.Valve. Dis* ; 15(2), p: 225-229.
- Bittle J.A. , Levin D.C. , (1997). Coronary arteriography in Braunwald Heart disease: A Textbook of Cardiovascular Medicine fifth edition. Saunders WB, Philadelphia ; p: 240-272.
- Brown B.G. , Bolson B. , Frimer M. , Dodge H.T. , (1977). Quantitative coronary arteriography. *Circulation*; 55, p: 329- 337.
- Bugiardini R. , Badimon L. , Collins P. , (2007). Angina, "normal" coronary angiography, and vascular dysfunction: risk assessment strategies. *PLoS. Med* ; 4(2), p: 2.
- Camine D.C. , (2007). Anatomy: A regional atlas of the human body. Fifth edition, Lippincott Williams and Wilkins; chapter 2, p: 138-139.
- Cavalcanti J.S. , Lucena O.M. , Paise M.A.V. , Balaban G., Andrade O.C. , Lucena O.E. , (1995). Anatomic variations of the coronary arteries. *Arq. Bras. Cardiol* ; 65(6), p: 489- 492.
- Charles F. , Davies M.J. , Webb-peploe M.M. , (1973). Length of left main coronary artery. *Brit. Heart. J*; 35, p: 796-798.
- Cheemalapati S. , Sachin T. ,Gurpreet G. , Arkalgud S. , Arkalgud S.K. , (2006). Normal coronary artery dimension in Indians. *Ind. J. Thrac. Cardiovas. Surg* ; 22, p: 159-164.
- Cohen M.V. , (1985). Coronary collaterals: Clinical an expereriment observation. *Future. Publ. Co*; p: 1-91.
- Connolly J.E. , (2002). The development of coronary artery surgery: personal recollections. *Tex. Heart. Inst. J*; 29, p: 4-10.
- Dhall U. , Chaudhary S. , Sirohiwal B.L. ,(2003). Histomorphometri analysis of coronary arteries: sexual dimorphism. *Journal of the anatomical society of India* ;Vol 52, No.2, p: 07-12.

- Dhawan J. and Bray C.L. , (1995). Are Asian coronary arteries smaller than Caucasian? A study on angiographic coronary artery size estimation during life. *Int. J. Cardiol* ; 49, p: 267-269.
- Dlear Z. , Kenneth M.T. , Jens P.B. , (2006). Coronary artery size and disease in UK South Asian and Caucasian men. *Eur. J. Cardiothorac. Surg* ; 29, p: 492-495.
- Dodge J.T. , Brown B.G. , Bolson E.L. , Dodge H.T. , (1992). Lumen diameter of normal human coronary arteries .Influence of age, sex, anatomic variation and left ventricular hypertrophy or dilatation.*Circulation* ; vol 86, p: 232-246.
- Douglas P.Z., Peter L., Robert O.B., Braunwald E., (2005). *Heart Disease: A text book of cardiovascular medicines*, seventh edition, Elsevier Saunders, USA; chapter 18, p : 426-427.
- Ehrlich W. , Dela C.C. , Cohn A.E. , (1931). Anatomical ontogeny; A study of the coronary arteries. *Am. J. Anat* ; 49, p: 241-282.
- Eren S. , Bayran E. , Fil F. , Koplay M. , Sirvanci M. , Duran C. et al,(2008). An investigations of the association between coronary artery dominance and coronary artery variations with coronary arterial disease by MSCT angiography. *Turkey J. Comput. Assist.Tomogr* ; 32(6), p: 929-33.
- Fleagle S.R. , Jonson M.R. , Wilbricht C.J. , Skorton D.J. , Wilson R.F. , White C.W. et al, (1989). Automated analysis of coronary arterial morphology in cineangiograms: Geometric and physiologic validation in human. *IEEE. Trans. Med. Imaging* ; 8, p: 387-400.
- Frank S. , Akinori C. , Carolina L. , Liana A. , Luciene N. , Samuel S. , (2008). Study of sinoatrial artery dominance in Brazilian human hearts. *Int. J. Morphol* ; 26(1), p: 47-50.
- Frederic H.M. , Michael J.T. , Robert B.T. , William C.O. , Claire W.G. , Kathleen W. et al, (2003). *Human anatomy*. Foruth edition, Pearson education international; chapter 21, p: 560-561.
- Fuster V. , Alexander R.W. , O'Rourke R.A. , (2001). *Hurst's The Heart* tenth edition. Mc. Graw. Hill ; p: 53.
- Gazetopoulos N. , Ionnidis P.J. , Marselos A. , Kelekis D. , Lolas C. Avgoustakis D. , (1976). Length of main left coronary artery in relation to atherosclerosis of its branches. A coronary arteriographic study. *Brit.Heart. J*; 38, p: 180-185.
- Goodman S. , (2001). Pharmacologic management of patients undergoing conscious sedation. *Clin. Nurse. Spes* ; 15, p: 269.
- Greenberg M.A. , Frisch B.G. , Spindola F.H. , (1989). Congenital anomalies of the coronary arteris. Classification and significance. *Radiol, Clin. N. Amer* ; 27, p: 1127-
- Harrison D.G. , White C.W. , Hiratzka L.F. , Doty D.B. , Barnes D.H. , Eastham C.L. et al, (1984). The value of lesion cross-sectional area

- determined by quantitative coronary angiography in assessing the physiologic significance of proximal left anterior descending coronary arterial stenosis. *Circulation* ; 69, p: 1111-1119.
- Hermiller J.B. , Cusma J.T. , Spero L.A. , Fortin D.F. , Harding M.B. , Bashore T.M. , (1992). Quantitative and qualitative coronary angiographic analysis : review of methods, utility and limitations. *Cathet. Cardiovasc. Diagn* ; 25, p: 110-131.
- Hermiller J.B. , Buller C.E. , Tenaglia A.N. , Kisslo K.B. , Philips H.R. , Bashore T.M. et al, (1993).Unrecognized LMCA disease in patients undergoing interventional procedures. *Am. J. Cardiol* ; 71, p: 173-176.
- Herrman J.R. , Keane D. , Ozaki Y. , Boerden A. , Serruys P.W. , (1994). Radiological quality of coronary guiding catheters: a Quantitative analysis. *Cathet. Cardiovasc. Diagn* ; 33(1), p: 55-60.
- Huma K. , Aijaz A. , Nafis A. , (2006). Comparative histology of coronary arteries in mammals. *J. Anat. Soc. India*; 55(1), p: 27-30.
- Hurst J.W. , (2004). Hurst's The Heart. Medical publishing, New York: Division; p: 489-490.
- Hutchins G.M. , Bulkley B.H. , Miner M.M. , Boitnott J.K. (1977). Correlation of age and heart weight with tortuosity and caliber of normal human coronary arteries. *Am. Heart. J*; 94, p: 196-202.
- Hutchins G.M. , Nazarian I.H. , Buikley B.H. , (1978). Association of left dominant coronary arterial system with congenital bicuspid aortic valve. *Am. J. Cardiol* ; 42(1), p: 57-59.
- Iliia R. , Rosenshtein G. , Weinstein J. , Cafri C. , AbuFul A. , Gueron , (2001). Left anterior descending artery length in left and right coronary artery dominance. *Coron. Artery. Dis* ; 12(1), p: 77-78.
- Inderbir S. , (2007). Text book of anatomy with colour atlas. Fourth edition, Ajanta Offset and Packagings Ltd ; volum two, chapter 33, p: 874-881.
- Ito H. , Tomooka T. , Sakai N. , (1992). Lack of myocardial perfusion immediately after successful thrombolysis. A predictor of poor recover left ventricular function in anterior myocardial infarction. *Circulation* ; 85, p: 1699- 1705.
- James T.N. , (1961). Anatomy of the coronary arteries. Paul. B. Hoeber ; p: 12-150
- Johnson M.R. , Skorton D.J. , Ericksen E.E. , Fleagle S.R. , Wilson R.F. , Hiratzka L.F. et al, (1988).Videodensitometric analysis of coronary stenosis: In vivo geometric and physiologic validation in human. *Invest. Radiol* ; 23, p: 891-898.
- Jose R. , Luisa C. , Luciana S. , (2003).The posterior ventricular branches of the coronary arteries in the human heart. *Arquivos. Brasileiros. De. Cardilogia* ; volume 82, p: 468-472.

- Kaimkhani Z.A. , Ali M.M. , Faruqi A.M. , (2005). Pattern of coronary arterial distribution and its relation to coronary artery diameter. Journal of Ayub Medical College, Abbottabad ;JAMC; 17(1), p: 40-43.
- Kaimkhani Z. , (2004). Coronary artery diameter in a cohort of adult Pakistani population. Journal of the Pakistan Medical Association; vol 54 n°5, p: 259-269.
- Kalpana R. , (2003). A study on principal branches of coronary arteries in humans. J. Anat. Soc. India ; 52(2), p: 137-140.
- Kim S.G. , Apple S. , Mintz G.S. , McMillan T. , Canos D.A. ,Maehara A. et al, (2004). The importance of gender on coronary artery size: invivo assessment by intravascular ultrasound. Clin. Cardiol. May; 27(5), p: 291-294.
- Koiwa Y. , Bahn R.C. , Ritman E.L. , (1986). Regional myocardial volume perfused by the coronary artery branch estimation in vivo. Circulation; 74, p: 157-163.
- Leung W.H. , Studius M.L. , Alderman E.L. , (1991). Determinant of normal coronary artery dimension inhuman. Circulation. J; 84, p: 2294-2306.
- Lewis B.S. and Gotsman M.S. , (1973). Relation between coronary artery and left ventricular wall mass. Br. Heart. J; 35, p: 1150-1153.
- Lewis C.M. , Dagenais G.R. , Friesingers G.C. , Ross R.S. , (1970).Coronary arteriographic appearances in patient with left bundle-branch block. Circulation ; 41, p: 299-307.
- Lip G.Y.H. , Rathore V.S. , Katira R. , Watson R.D.S. , Singh S.P. , (1999). Do Indo-Asiana have smaller coronary arteries? Postgrad. Med. J; 75, p: 463-466.
- Luiz C. and Jose C. , (2005). Basic Histology, eleventh edition, McGraw-Hill ; chapter 11, p: 211.
- MacAlpin R.N. , Abbasi A.S. , Grollman J.H. , Eber L. , (1973). Human coronay artery size during life: A cinearteriographic study. Radiology. J; 108, p: 567-576.
- Marieb E.N. , Jon M. , Wilhelm P.B. , (2008). Human Anatomy. Fifth edition, Pearson Education Inc; chapter 18, p: 544-545.
- Mcconnell M.V. , Ganz P. , Selwyn A.P. , Li W. , Edelman R.H. , Manning W.J. , (1995). Identification of anomalous coronary arteries and their anatomic course by magnetic resonance coronary angiography. Circulation ; 92, p: 3158-316
- Moore A. and Dalley F. , (2006).Clinically oriented anatomy, fifth edition, Lippincott Williams and wilkins ; chapter one, p: 156-157.
- Murphy E.S. , Rosch J. , Rahimtoola S.H. , (1977). Frequency and significance of coronary arterial dominance in isolated aortic stenosis. Am. J. Cardiol ; 39(4), p: 505-509.

- Nafis A.F. and Aijaz A.K. , (2006). Manual of practical anatomy. CBS Publishers and distributors; volum 2, chapter 14, p: 61-64.
- Neufeld H.N. , Wagenvoort C.A. , Edwards J.E. , (1962). Coronary arteries in fetuses, infant's juveniles and young adults. Clin. Invest ; 11, p: 837- 844.
- Neufeld H.N. and Schneeweiss A. , (1983). Coronary artery disease in infant and children. Lea and Febiger; Philadelphia; p: 65-78.
- Nils K. , Ernst L. , Markus S. , Marianne Z. , Yves A. , Christian S. et al, (2001). Gender differences in coronary artery size per 100g of left ventricular mass in a population without cardiac disease. Swiss. Med. Wkly ; 131, p: 610-615.
- Nowak D. , Gielecki J. , Zurada A. , Goralczyk K. , (2009).No relationship between the length of the left coronary artery main stem and the type of coronary vasculature in human fetus from a morphological perspective. Med. Sci. Monit ; 15(1), p: 20-25.
- Ogden J.A. , (1968). Congenital variation of the coronary arteries: A clinico pathologic survey. Yale University School of Medicine, New Heaven Thesis ; p: 25-27.
- O'Keefe J.H. , Owen R.M. , Bove A.A. , (1987). Influence of left ventricular mass on coronary artery cross-sectional area. Am. J. Cardiol ; 59, p: 1395-1397.
- Pamela C.B.M. and John F.M. , (2005). Oxford text book of functional anatomy. Second edition, Oxford University Press; vol 2, chapter 5, p : 74-75.
- Paulin S. , (1983). Normal coronary anatomy. In: Abrams HL (ed): Coronary arteriography. A practical approach. Little. Brown. Co. Boston ; p: 127-174.
- Paulsen S. , Vetner M. , Hagerup C.M. , (1975). Relationship between heart weight and the cross-sectional area of the coronary ostia. Acta. Pathol. Microbiol. Scand ; 83, p: 529-532.
- Peikovic B. , Krainc I. , Anderhuber F. , Kosutic. , (2008). Anatomical aspects of the arterial blood supply to the sinoatrial and atrioventricular nodes of the human heart. J. Int. Med. Res ;36(4), p: 691-698.
- Perimutt L.M. , Jay M.E. , Levin D.C. , (1983). Variations in the blood supply of the left ventricular apex. Invest. Radiol ; 18(2), p: 138-140.
- Post J. , Rossum A.C. , Bronzwaer J.G. , Cock C.C. , Hofman M.B. ,Valk J. et al , (1995). Magnetic resonance angiography of anomalous coronay arteries: a new gold standard for delineating the proximal course. Circulation ; 92, p: 3163-3171.
- Proudfit W.L. , Shirey E.K. , Sones F.M.J. , (1966). Selective cine coronary arteriography .Correlation with clinical finding in 1000 patients. Circulation ; 33, p: 901-910.
- Ratib O.M. and Mankovich N.J. , (1988). Quantitative coronary arteriography: design and validation. Radiology ; 167, p: 743- 747.

- Reig J. and Petit M. , (2004). Main trunk of the left coronary artery: anatomic study of the parameters of clinical interest. *Clin. Anat. J* ; 17(1), p: 6-13.
- Reig V. , (2003). Anatomical variation of the coronary arteries: The most frequent variations. *Eur. J Anat* 7 suppl ; 1, p: 29-41.
- Rensing B.J. , Hermans W.R.M. , Deckers J.W. , Feyter P. , Tijssen J.G.P. , Serruys P.W. , (1992). Lumen narrowing after percutaneous transluminal coronary balloon angioplasty follows a near Gaussian distribution: A quantitative angiographic study in 1,445 successfully dilated lesions. *J. Am. Coll. Cardiol* ; 19, p: 939-945.
- Restrepo C., Eggen D.A. , Guzman M.A. , Tejada C. , (1973). Postmortem dimensions of the coronary arteriea in different geographic location. *Lab. Invest* ; 28, p: 244-251.
- Roberts C.S. and Roberts W.C. , (1980). Cross-sectional area of the proximal portions of the three major epicardial coronary arteries in 98 necropsy patints with different coronary events: relationship to heart weight, age and sex. *Circulation* ; 62, p: 953-959.
- Rodriguez F.L. and Robbin S.L. , (1959). Capacity of human coronary arteries : a postmortem study. *Circulation* ; 19, p: 570-578.
- Ropers D. , Moshage W. , Daniel W.G. , Jessl J. , Gottwik M. , Achenbach S. , (2001). Visualization of coronary artery anomalies and their anatomic course by contrast-enhanced electron beam tomography and three-dimensional reconstruction. *Am. J. Cardiol* ; 87, p: 193-197.
- Sadler T.W. , (2006). *Medical embryology*.10th edition, Lippincott Williams and Wilkins ; chapter 12, P: 184-185.
- Said H.S. , Olumbe A.O. , Kalebi A. , (2002). Anatomy and pathology of coronary artery in adult black Kenyans. *East. Afr. Med. J*; 79(6), p: 323-327.
- Sanudo J.R. and Mirapeix , (1998). Right coronary artery arising from the left aortic sinus in a heart with left coronary dominance: a postmortem description a case report. *Angiography* ; 49(3), p: 239-242.
- Schlesinger M.J. , (1940). Relation of anatomic pattern to Pathologic conditions of the coronary arteries. *Arch. Path. J*; 30 , p: 403-415.
- Schlesinger M.J. , Zoll P.M. , Wessler S. , (1949). The conus artery: A third coronary artery. *Am. Heart. J* ; 38, p: 823-836.
- Seldinger S.I. , (1953). Catheter replacement of the needle in percutaneous arteriography, a new technique. *Acta. radiol* ; 39, p: 368.
- Sinnatamby C.S. , (2006). *Last's Anatomy*, eleventh edition, Churchill Living stone; chapter 4, p: 204-212.
- Skelton T.N. , Kissio K.B. , Mikat E.M. , Bashore T.M. , (1987). Accuracy of digital angiography for quantitation of normal coronary luminal segments in excised, perfused hearts. *Am. J. Cardiol* ; 1, 59(15), p: 1261-1265.

- Snell R.S. , (2004). Clinical anatomy. Seventh edition. Lippincott Williams and Wilkins; chapter two, p: 110-119.
- Snell R.S. , (2008). Clinical anatomy by region. Eighth edition. Lippincott Williams and Wilkins; chapter two, p: 105-114.
- Sones F.M. , Shirey E.K. , (1962). Cine coronary arteriography. Mode Concepts. Cardiovasc. Dis ; 31, p: 735-738.
- Spindola F.H. , Grose R. , Solomon N. , (1983). Dual left anterior descending coronary artery: Angiographic description of important variants and surgical implications. Am. Heart. J; 105, p: 445-455.
- Standing S. , Harold E. , Jeremiahc H. , David J. , Andrew W. , Patricia C. et al, (2005). Grays anatomy, the anatomical basis of clinical practice. thirtyninth edition, Elsevier Churchill living stone; chapter 60, p: 1014-1018.
- Tadeharar F. ,Imazu M. , Kono S. , Sano K. , (2001). Calibration with currently available low- radiopacity catheters for scaling in digital quantitative coronary angiography. Invest. Radiol ; 36(12), p: 705-712.
- Tarantini G. , Razzolini R. , Cacciavillani L. et al, (2006). Influence of transmural, infarct size and severe microvascular obstruction on left ventricular remodeling and function after primary coronary angioplasty. AM. J. Cardiol ; 98, p: 1033-1040.
- Topaz O. , Disciascio G. , Cowley M.J. , Soffer A. , Lanter P. , Goudreau E. et al, (1991). Absent left main coronary artery: angiographic findings in 83 patients with separate ostia of the left anterior descending and circumflex arteries at the left aortic sinus. Am. Heart. J ; 122(2), p: 447-452.
- VantHof A.W. , Liem A. , Suryapranata H. , Hoorntie I.C. , Deboer M.J. , Zijlstra F. , (1998). Angiographic assessment of myocardial reperfusion in patints treated with primary angioplasty for acute myocardial infarction: myocardial blush grade. Zwolle myocardial Infarction study group. Circulation ; 97, p: 2302-2306.
- Vasheghani F.A. , Kassaian S.E. , Yaminisharif A. , Davoodi G. , Salarifar M. , Amirzadegan A. , (2008). The association between coronary arterial dominancy and extent of coronary artery disease in angiography and para clinical studies. Clin. Anat ; 21(6), p: 519-523.
- Vieweg W.V.R. , Alpert J.S. , Hagan A.D. , (1976). Caliber and distribution of normal coronary arterial anatomy. Cathet. Cardiovasc. Diagn ; 2, p: 269-280.
- Vikram S. , Jayaprasad N. , Praveen S.V. , Mubarak, Babu V. , Kder M. , (2005). Normal coronary artery dimensions in Kerala populations : An angiographic study. Indian Heart J ; 57(5) No. 446.
- Vogel R.A. , (1984). The radiographic assessment of coronary blood flow parameters. Circulation ; 72, p: 460-465.

Voldaver Z. , Neufeld H.N. , Edwards, (1975). Coronary arterial variations in the normal heart and in congenital heart disease. Academic. Press ; p: 19-22.

Voldaver Z. , Amplatz K. , Burchell H.B. , Edwards J.E. , (1976). Coronary heart disease. Clinical, Agiographic and Pathologic profiles. Springer. Verlag ; p: 123-158.

Waller B.F. , (1983). Five coronary ostia: Dublicate left anterior descending and right conus coronary arteries. Am. J. Cardiol ; 51, p: 1562.

Wilens S.L. , Plair C.M. , Henderson D.H. , (1966). Size of the major epicardial coronary arteries at necropsy: Relation to age, heart weight and myocardial infarction. JAMA ; 198, p: 1325-1329.

Zainul A. , Judith G. , (1978). Origin and length of left main coronary artery: Its relation to height, weight, sex, age, pattern of coronary distribution and presence or absence of coronary artery disease. Catheterization and Cardiovascular Diagnosis J.

Zamir M. and Sinclair P. , (1988). Roots and calibers of the human coronary arteries. Am. J. Anat ; 183, p: 226-234.

Zumbo O. , Fani K. , Jarmolych J. , Daoud A.S. , (1965). Coronary atherosclerosis and myocardial infarction in hearts with anomalous coronary arteries. Lab. Invest ; 14, p: 571-576