

MANAGEMENT OF FIBULAR HEMIMELIA (CONGENITAL ABSENCE OF FIBULA) USING ILIZAROV METHOD IN SULAIMANI

*Ass. Prof. Dr. Omer Ali Rafiq Barawi,
Ass. Lecturer Zmnako J. Amen*

School of Medicine, University of Sulaimani, Kurdistan Region, Iraq

Abstract

Background: Fibular hemimelia is the most common congenital deficiency of long bones. Therefore, it is characterized by a wide spectrum of manifestations ranging from mild limb length inequality to sever shortening with foot and ankle deformities and associated anomalies.

Objectives: To evaluate the results of ankle and foot reconstruction and limb length equalization in patients with Fibular Hemimelia.

Patients and Methods: A prospective study was carried out on 40 limbs in 32 patients with fibular hemimelia during the periods of March 2010 to January 2014. Male to female ratio was 24:8. Their age ranged at an average between 2-16 years (9 years). The reconstruction of ankle and foot was done. Also, the equalization of the limb was done also using Ilizarov frame.

Results: The result of this study was assessed using the Association for the Study of Applications of Methods of Ilizarov (ASAMI) scoring system. Therefore, the final results were: Failure rate with 2 limbs 5%, Poor with 2 limbs 5%, Fair with 2 limbs 5%, Good with 8 limbs 20%, and Excellent with 26 limbs 65%.

Conclusion: In conclusion, the Ilizarov method is an attractive alternative method used for the management of selected fibular hemimelic patients having three or more toes who are refusing amputation.

Keywords: Fibular Hemimelia, Fibular anlage, Limb Length Inequality in Fibular Hemimelia.

Introduction

The word “Hemimelia” originates from the Greek word “Hemi and melos” i.e. half limb (Subhra et al., 2015). However, Fibular Hemimelia is a deformity with longitudinal deficiency of fibula which may be partial or complete. Also, there is a wide spectrum of abnormality which affects a part of or the entire lower limb, from the proximal femur to the toes. In fibular

hemimelia (congenital absence of Fibula), the management of the Fibular Hemimelia is done using the Ilizarov method (Ruta Kulkarni, Text book of orthopaedics and trauma 2nd.ed. 2008, p.1686-1691).

Consequently, Fibular Hemimelia was first described by Gollier in 1698. Knee instability presents itself as a posterior subluxation of tibia on the femur during limb lengthening (Deborah Stanitski, S.Robert Rozbruch, and M.D. Svetlana Ilizarov, 2007).

Prevalence rate was estimated at 1 in 40.000 births. However, the case is apparent at birth and can vary from mild limb length inequality and asymmetry, to sever shortening with wide range associated anomalies. Bilateral involvement is not uncommon with a reported prevalence of 9-52%. Thus, male to female ratio is 2:1. However, studies have reported that the incidence is more common in females compared to males (Graham, 1983; Boakes et al., 1991; Hall and Miyake, 2000; Birch et al., 2011; Hazem and Amin, 2012; Hootnick et al., 1980; Kim, 2012)

Associated Anomalies

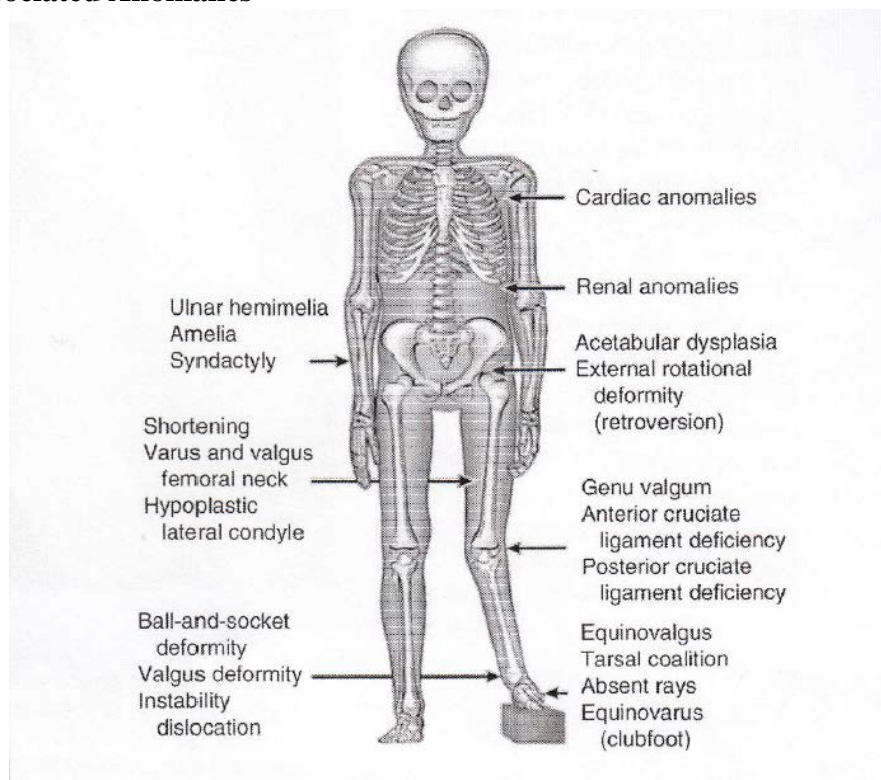


Figure (1). Skeletal diagram of a 13 years old child demonstrating the associated anomalies of congenital fibular deficiency (Hamdy et al., 2014)

1. Proximal Focal Femoral Deficiency may occur in about 15% of the cases. Thus, these cases include femoral shortening, valgus distal femur, hypoplastic lateral femoral condyle, retroversion of femur and bifid femur, Distal Femoral Duplication, and Fibular Agenesis Associated with Congenital Cardiac Defect (Ruta Kularni, 2008; Murat Cakir et al., 2010);
2. Tibial shortening and anteromedial bowing (procarvatum and valgum);
3. Knee instability anteroposterior due to cruciate ligament deficiency;
4. Ankle Ball and socket ankle, equinovalgus. Tarsal coalition such as talocalcaneus fusion and absent of lateral rays on the foot;
5. Limb Length Discrepancy; and
6. Acetabular Dysplasia (Gaine and McCreath, 1996).

Classifications

Consequently, most of these classifications were described at the time where amputation and prosthetic limb equalization was unsuccessful. Thus, this was the only reliable treatment and surgical reconstructions for fibular hememila (Dror Paley, www.PaleyInstitute.org, dpaley@lengthening.us).

Treatment Oriented Classification by Dror Paley classifies **Fibular Hememila into four (4) types** (www.Paleyinstitute.org, dpaley@lengthening.us).

Table 1. Achterman and Kalamchi classification System for Congenital Fibular Deficiency (Hamdy et al., 2014).

| Type | Description |
|------|--|
| IA | Fibula is present. Proximal fibular epiphysis is distal to the level of the tibial growth plate. The distal fibular growth plate is proximal to the dome of the talus. |
| IB | Partial absence of the fibula. The fibula is absent for 30% to 50% of its length proximally. Distally, the fibula is present but does not support the ankle. |
| II | Complete absence of the fibula. |

Stanitski Classification

In stanitski classification, Type I delineates nearly normal, Type II delineates miniature, and Type III delineates absent fibula. Horizontal (H), spherical (S) or valgus (V), delineates the ankle joint shape. Also, a small subscript "C" delineates a coalition. Thus, the number of rays (1-5) is then expressed numerically. Coalition in itself is not a reason for amputation. As a result, careful explanation is required to be made to the parents that this will never be a normal mobile hind foot (Stanitski, 2007)

Birch Classification

Recently, Birch et al proposed a new classification system that takes into consideration the functionality of both feet and upper extremities, as

well as the percentage of Limb Length Inequality (Birch et al., 2011 and Hamdy et al., 2014)

The etiology of Congenital Fibular Deficiency remains unclear. Most cases are sporadic. However, chromosomal anomalies and autosomal dominant, autosomal recessive, and X-linked transmission have been reported (Hamdy et al., 2014).

Sixty percent of patients with complete Congenital fibular deficiency (CFD) have a palpable posterior band (fibular anlage), representing a fibrocartilagenous fibular remnant. Therefore, this anlage produces tethering effects that leads to tibial bowing. Knee abnormalities include genuvalgum, Anterior Cruciate Ligament (ACL) deficiency, patella Alta, and hypoplastic patella (Hamdy et al., 2014).

The primary problems in CFD are the Limb Length Inequality (LLI). Furthermore, treatment should be individualized for each patient. A multidisciplinary team, including the Surgeon, occupational and physical therapists, orthotist, prosthetist, social worker, and pediatric psychologist, would be beneficial.

However, many authors agree that the rate of complications increases significantly when the limb segments are lengthened from 15% to 20% (Hamdy et al., 2014).

Other associated anomalies include cardiac thrombocytopenia, absent radius (TAR) syndrome, thoracoabdominal schisis, spina bifida, and renal anomalies (Rabah et al., 2014). Fibular hemimelia occurs due to interference with the limb bud development. Hence, this is about the 5th or 7th of intrauterine life. The fibular field of the limb of the bud controls the development of the proximal femur which explains the frequent association of femoral anomalies (Rabah et al., 2014).

PATIENTS AND METHODS

A prospective study was carried out on 40 limbs in 32 patients with Fibular Hemimelia treated between March 2010 and January 2014. Thus, they were 24 boys and 8 girls. Their age ranged at an average between 2-16 years (9 years). For 8 patients, 25% had bilateral Fibular Hemimelia, while for the remaining 24 patients, 75% had unilateral Fibular Hemimelia.

True size plain radiograph anteroposterior and lateral views of the leg were done in addition to standing full length Scanogram of the lower limbs. Preoperative investigations were done, including Echocardiography. However, cases were classified according to Achterman and Kalamchi classification shown in table 2.

Table 2. Details of cases and their treatment.

| Types | No. of limbs | Surgical procedure |
|-------|--------------|--|
| IA | 7 | Correction & elongation of tibia |
| IB | 10 | Reconstruction of ankle & foot, and equalization of the limb |
| II | 2 | Amputated |
| | 19 | Excision of anlage, Reconstruction of ankle & foot, and equalization of the limb |
| | 2 | Anlage was used as buttress to stabilize the ankle & foot plus the limb length equalization. |

Twenty three of the limbs were Type II. Thus, for 2 of them, Symes' amputation was done. For the remaining 21 limbs of Type II with limb shortening 7-11 cm average 9cm, reconstruction of ankle and foot was done, followed by limb length equalization one month later. Out of 2 of the 21 limbs, the fibular anlage was used as a buttress for giving better stabilization to ankle and foot. Nevertheless, in 19 of them, excision of fibular anlagen was done and sent for histopathological examination as shown in Figure (2).

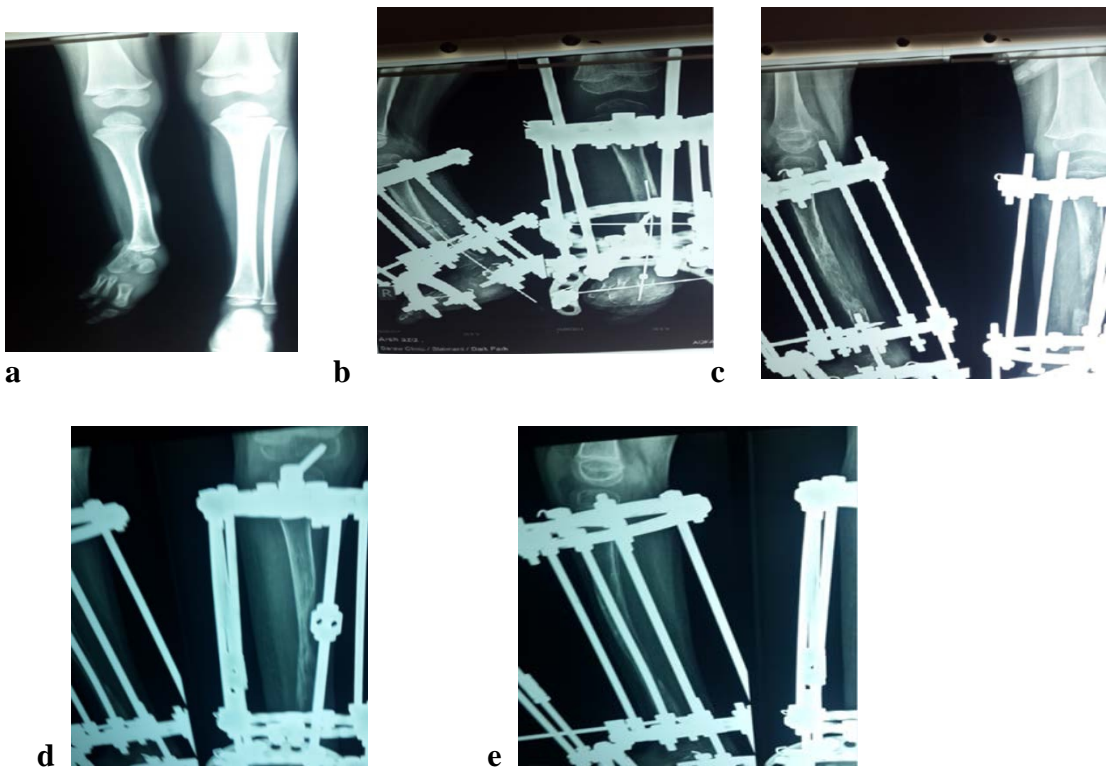

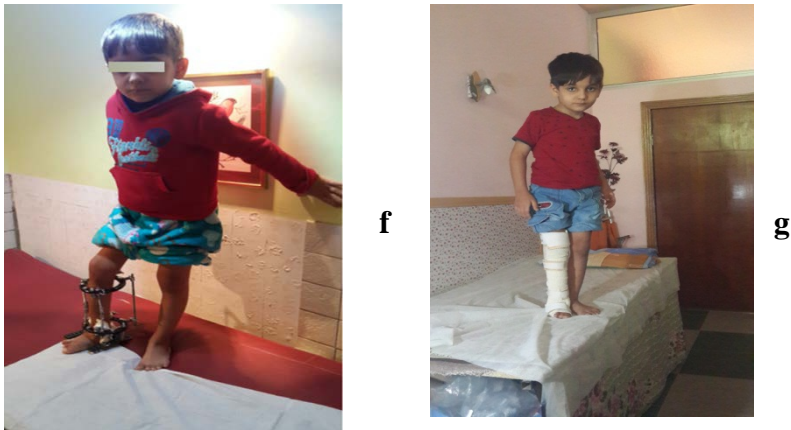
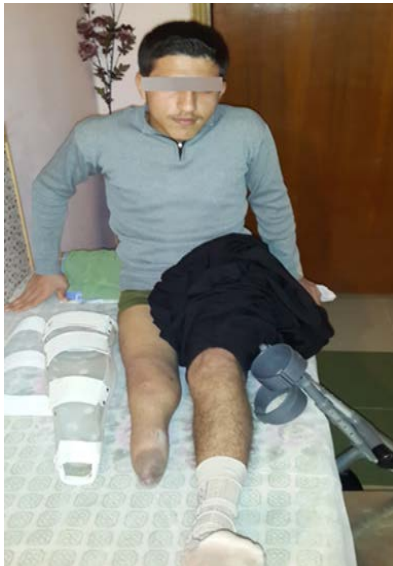
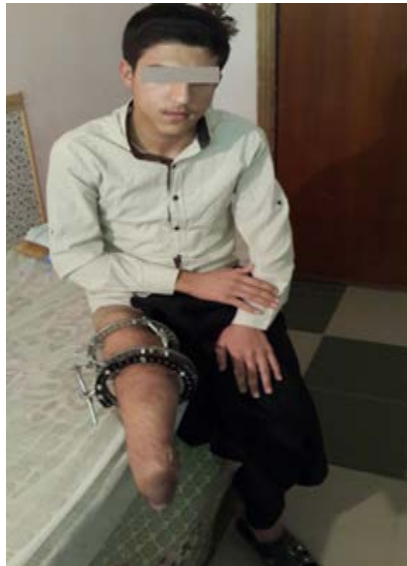
Figure (2): a. Plain radiograph of legs of six years old boy with Type II right fibular hemimelia, absent outer two digits and equino valgus. **b.** Radiograph of the same patient after reconstruction of ankle and foot, and after corticotomy of tibia was done. **c.** Radiograph of the same patient after distraction of tibia by 7 cm. **d & e.** Anteroposterior and lateral views of plain radiograph of the same patient with consolidation of distraction site. **f.** The same patient with Ilizarov frame. **g.** The same patient after removal of Ilizarov frame.

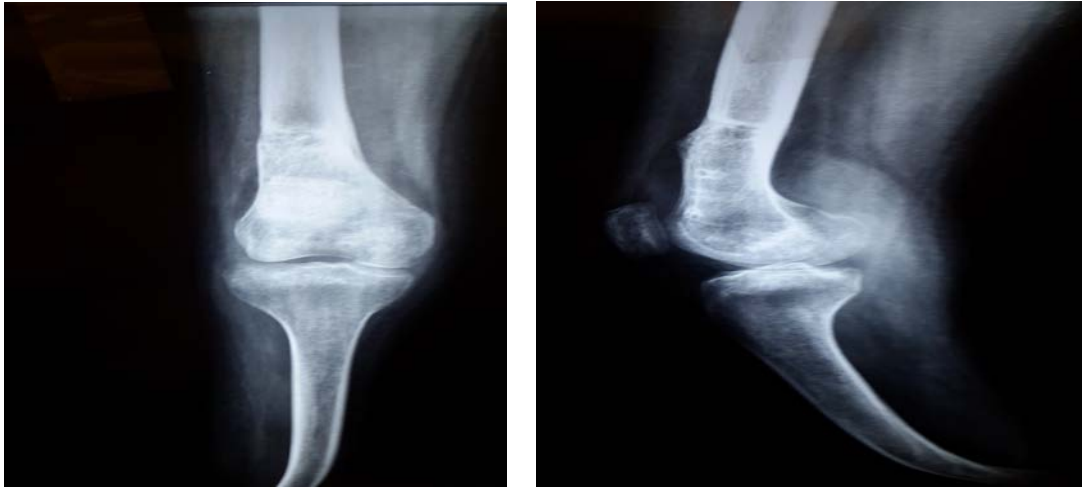For one of those 2 amputee patients, supracondylar femoral hemicallotasis was done.



a.

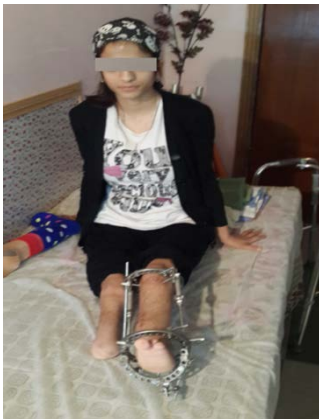

b.

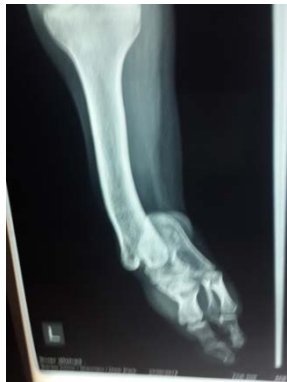

c. **d**
Figure (3): a. Sixteen years old boy with right Fibular Hemimila. Supra condylar femoral hemicallotasis was done using Ilizarov Frame. **b.** After removal of Ilizarov Frame, there was no more genu valgus. **c & d** Anteroposterior and Lateral views of plain radiograph of the same patient showing well consolidated supra condylar femoral hemicallotasis.

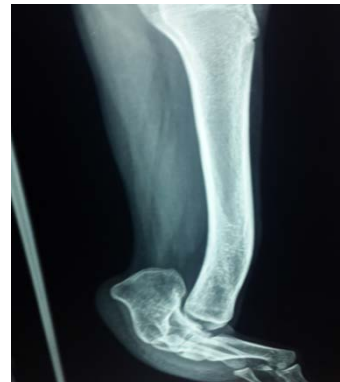Furthermore, the second amputee patient was the bilateral Fibular Hemimelic patient. Therefore, the elongation of non-amputated site was done at 8 centimeter. In addition, treatment of associated Rocker Bottom deformity by gradual elongation of tendoachillis and horizontal osteotomy of calcaneus was carried out as shown in Figure (4).



a.



b.



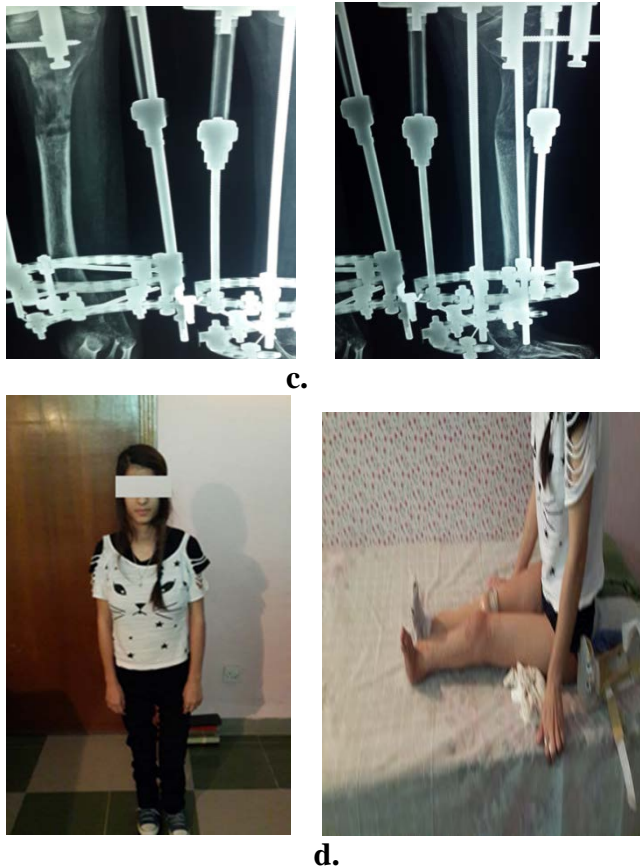
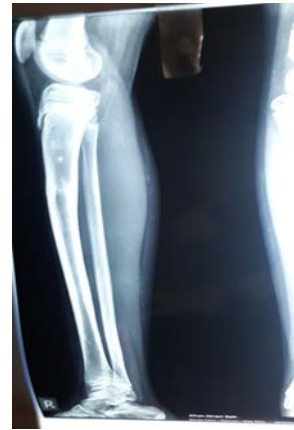
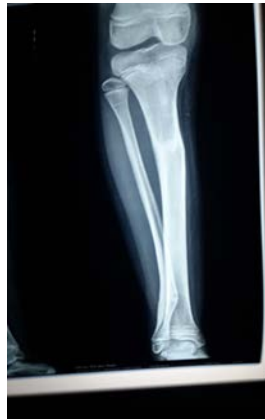
Figure (4): a. Fourteen years old girl with bilateral fibular hemimelia left tibial correction, and elongation was done with the correction of Rocker bottom deformity. **b.** Plain radiograph of the left leg of the same patient A.P. and lateral views with Type II fibular hemimelia, Rocker bottom deformity and coalition of talus, and calcanus and absent outer two digit. **c.** The plain radiograph A.P. and lateral views of the same patient with destruction of tibia (7 cm). **d.& e.** After the removal of the Ilizarov frame, the same patient can stand without support.

From the total cases, 17 limbs were type I Fibular Hemimelia, 7 of them Type I-a with 3-4 cm shortening (average 3.5 cm) in which tibial correction and elongation were done for them (**Figure (5)**). However, the remaining 10 of them were of Type II-b with 5-7 cm (average 6 cm) in addition to correction and elongation of tibia. Then, it is preceded by the reconstruction of associated ankle and foot deformities so that the Ilizarov frame is extended to hold the ankle and foot in the corrected position.



a.



b .

Figure (5) a. Ten years old girl with Type I-a right fibular hemimelia after elongation of tibia by 4 cm after the Ilizarov frame has been removed. **b.** Plain radiograph of right leg of the same patient A.P. & Lateral views showing consolidated distraction site. Thus, there is small residual valgus deformity of the leg.

Results: The results of this study were assessed using Association for the Study of Applications Methods of Ilizarov (ASAMI) scoring system.

Table 2: Association for the Study and Application of the Methods of Ilizarov (ASAMI) scoring system (Shahid et al., 2008; Mohammad et al., 2010)

| Bone Results | |
|---------------------------|---|
| Excellent | Union, no infection, deformity < 7° limb length discrepancy <2.5cm. |
| Good | Union + any two of the followings: No infection, deformity <7 ° limb length discrepancy < 2.5cm. |
| Fair | Union + only one of the following: No infection, deformity <7° limb length discrepancy <2.5 cm. |
| Poor | Non-union /refracture /union + infection + deformity< 7 ° + limb length discrepancy >2.5 cm. |
| Functional Results | |
| Excellent | Active, no limp, minimum stiffness (loss of < 15 ° knee extension/<15° dorsiflexion of ankle), no Reflex Sympathetic Dystrophy, Insignificant pain. |
| Good | Active with one or two of the followings: Limp, stiffness, R.S.D., insignificant pain. |
| Fair | Active with three or all of the followings: Limp, stiffness, R.S.D., significant pain. |
| Poor | Inactive (unemployment or inability to return to daily activities because of injury). |
| Failure | Amputation. |

However, the final results were:

Failure rate 2 limbs 5%
 Poor 2 limbs 5%
 Fair 2 limbs 5%

Good 8 limbs 20%
Excellent 26 limbs 65 %
Mean Follow up Time is 1.5 years.
Average amount of shortening is 5 cm.
Average lengthening is 4.5 cm.
Mean healing time is 5 months.
Healing Index is 1 cm per Month.
Mean External Fixator Time is 5 months.

Consequently, most frequent complications include:

1. Pin tract infection, 4 cases 10%.
2. Depression, 2 cases 5%.
3. Equinus deformity, 10 cases 25%.
4. Knee dislocation, 6 cases 15%.
5. Decreased Range of Movement, 8 cases 20%.
6. Residual Limb Length Discrepancy, 4 cases 10%; mean discrepancy, 2 Cm.

Discussion

Fibular hemimelia has a wide range of severity ranging from mild hypoplasia of the fibula with minimal functional disturbance to complete absence and associated deficiency of lateral rays of the foot and tarsal bones.

From the total cases in this study, amputation was done for only 2 limbs. They were of Type II fibular hemimelia, having only one ray. Therefore, this concises with the conclusion which states that, at least three rays should be present for a foot to be considered as salvageable, whereas those with fewer than three rays are considered to be nonsalvageable (Murat Cakir et al., 2010). One of these two amputee cases was associated with distal femoral valgus causing knee pain. As a result, it was corrected gradually by supracondylar femoral hemicallotaxis using Ilizarov Frame. While the second amputee case was bilateral, the non-amputated side having three rays of the tibia was elongated by 7 centimeters. Also, the rocker bottom deformity was corrected gradually by elongating tendoachillis and horizontal osteotomy of calcaneus and through gradual distraction of osteotomy site (Alexander et al., 2004).

In the remaining 21 limbs with Type II Fibular Hemimelia in 2 of them, the fibular anlagen is used as a buttress to prevent recurrence of ankle and foot deformity, and for giving better stability to the ankle and foot (Subhra et al., 2105). In other 19 limbs, the fibular anlagen were excised as a way of preventing the recurrence of ankle and foot deformities (Ruta, 2008). Thus, they were sent for histopathological examination after the correction of ankle and foot deformities, correction and equalization of the limb done to correct valgus and the procarvatum of tibia. Seven limbs with Type Ia

elongation of tibia was done at 3-4 centimeter average (3.5 cm), while 10 limbs with Type Ib elongation of tibia was done at 5-7 centimeters average (6 cm). Furthermore, this is in addition to the correction of associated equinovalgus deformities by extending the Ilizarov frame to involve both the ankle and foot.

Preoperative true size plain radiograph of the elongating limb was taken which is important for preoperative assemble of the Ilizarov frame to shorten the operative time. Nevertheless, this is in compression to the progressive reconstruction of the frame intra-operatively. However, the main drawback of preoperative assembly is that you need to do preoperative sterilization of the frame. Also, the assistant should hold the frame during the application of the frame. Among those cases in which tibial elongation were done in 2 of them, the bone is shattered at the corticotomy site in one of them. However, this is due to inadequate number of holes done in the cortex of the bone. For the other one, it is due to the fact that the osteotome was not sharp enough. Nevertheless, despite the fact that a well consolidation of the distraction site happens, this may be because a wider osteoblastic surface is stimulated for osteogenesis.

In cases where femoral elongation (in addition to ankle and foot reconstruction and tibial correction and elongation) are needed for limb length equalization, the knee joint is also included in the Ilizarov external fixator frame to prevent posterior subluxation of tibia on the femur during limb lengthening (Robert and Svetlana, 2007).

Conclusion

The Ilizarov method is an attractive alternative method for the management of selected fibular hemimelic patients having three or more toes who are refusing amputation. Patient selection and satisfaction are very important factors for successful treatment. This is because patient and family motivation are very important factors for successful treatment of those patients who are refusing amputation, but prefers limb reconstructive procedures. Thus, this will be very helpful for the orthopedist to succeed in the treatment.

References

- Achterman and Kalmchi classification (1988). Sever progressive deformities after limb lengthening in Type II fibular hemimelia by Jack C.Y.Cheng, B.K.W. Ng *J Bone Joint Surgery (Br.)*; 80-B:772-6.
- Alexander Kirienko, Angelo Villa and Jason H. Calhoun (2004). Ilizarov Technic for complex foot and ankle deformities: Page (11,322- 323).
- Birch JG, Lincoln TL, Mack PW, Birch CM (2011). Congenital fibular Deficiency: A review of thirty years' experience at one institution and a

- Proposed classification system based on clinical deformity. *J Bone Joint Surg Am.* 93 (12):1144-1151.
- Boakes JL, Stevens PM, Moseley RF (1991). Treatment of genu valgus deformity in congenital absence of the fibula. *J Pediatr Orthop.* Nov-Dec.11 (6):721-4.
- Deborah Stanitski (2007). *Fibular Hemimelia, Text book of Limb Length and Reconstruction surgery.* informa Healthcare USA, Inc 449 .
- Dror Paley. *Fibular Hememila for parents frequently asked question* (www.PaleyInstitutue.org, dpaley@lengthening.us].
- Gainé WJ, McCreath SW (1996).Syme's amputation revisited: a review of 46 cases. *J Bone Joint Surg Br;* 78:674-82.
- Graham JM Jr.(1983). Limb anomalies as a consequence of spatially restricting uterine environments. *Prog.Clin. Biol Res.*110A:413-422.
- Hall BK, Miyake T. (2000). All for one and one for all: condensations and the initiation of skeletal development. *Bioessays.* 22:138-47.
- Hamdy, Asim M. Makhdom, Niel Saran, John Birch (2014).Congenital Fibular Deficiency Review Article Reggie C American Academy of Orthopaedic Surgeons April, Vol. 22,No 4,246- 254.
- Hazem Mossad El-Tayeby and Amin Abdel Razek Youssef Ahmed (2012).Ankle reconstruction in type II fibular hemimelia. *Strategies Trauma Limb Reconstr.* Apr; 7(1): 23–26.
- Hootnick DR, Levinsohn EM. Randall PA, Packard DS Rr. (1980).Vascular dysgenesis associated with skeletal dysplasia of the lower limb. *J Bone Joint Surg Am.* 62(7):1123-1129.
- Kim Suvama, Christopher Layton, and John Bancroft (2012). *Bncroft's Theory and practice of Histological Technique.* Churchill Livingstone.
- Mohammad Shabir, Mohammad Arif, Abdul Satar, Mohammad Inam (2010). Distraction osteogenesis in segmental bone defects in tibia by monoaxial external fixator. *JPMI;* 24 (2):133-137.
- Murat Cakir et al. (2010). Distal Femoral Duplication and Fibular Agenesis Associated with Congenital Cardiac Defect case report by *Indian Journal of Pediatrics,*Volume 77, February.
- Rabah M. Shawky, Heba Salah abd Elkahlek, Shaimaa Gad, and Shaimaa Abdelsattar Mohammad (2014). Unilateral proximal focal femoral deficiency, fibular aplasia, tibial campomelia, and oligosymdactyliy in an Egyptian child-Probable FFU syndrome. *The Egyptian Journal of Medical Human Genetics;* 15:299-302.
- Ruta Kulkarni (2008). *Fibular hemimelia (congenital absence of Fibula), Management of Fibular Hemimelia using the Ilizarov method.* Text book of Orthopaedics and Trauma, 2nd. Ed. p.1686-1691.

Shahid Hussain, Mohammad Inam, Muhammad Arif, Mohammad Shabir, and Israr Ahmad (2008). Limb Length Discrepancy in Lower Limb Management with unilateral external fixator. JPMI; 22 (4): 285-291.

Subhra Mandal, Prabir Mandal, and Basundhra Ghoshal (2015). Hemimelia: Mysetery Unrevealed, International Journal of Anatomy and Research, Vol. 3:958-62.ISSN 2321-4287.